

## Oral fibrinolytic agent in hyper-coagulopathy in severe COVID – 19 ARDS Patients: two case reports

Dimas Rio Balti<sup>1</sup>, Liem Audi Natalino<sup>2</sup>, Armyta Galuh<sup>3</sup>, Ryan Enast Intan<sup>4</sup>

### Abstract

The use of oral fibrinolytic agent (DLBS1033) has been proven for adjuvant treatment in venous thromboembolism, however until now there is no published report about its uses and effectiveness as an addition to the standard therapy of severe COVID-19 cases and hypercoagulopathy. We present two cases of severe confirmed COVID-19 from PCR tests, seen at Ngimbang Hospital, Lamongan, East Java in October and November, 2020. The first patient was a 51-year-old male who presented to ER with fever, dyspnoea, cough, and oxygen desaturation (SpO<sub>2</sub> room air 87%), with comorbid of pulmonary hypertension (PH), atrial fibrillation, heart failure secondary to cor pulmonale, and hypercoagulopathy. The second patient was a 56-year-old female who presented with fever, dyspnoea, and oxygen desaturation (SpO<sub>2</sub> room air 88%), with comorbid ARDS, hypertension, hyperglycaemia, hypercoagulopathy, heart failure, and CAD. Both of the patients were treated with standard treatment therapy for severe COVID-19 and comorbid therapy, and DLBS1033 in addition to fondaparinux due to limited hospital resources. Both patients showed good clinical outcomes after the course of treatment and had no adverse effects.

**Conclusions:** Our two case reports were the first that showed good clinical outcome and safety of DLBS1033 treatment in addition to fondaparinux for hypercoagulopathy therapy.

**Keywords:** Fondaparinux, Fibrinolytic, COVID-19, Dyspnoea, Atrial Fibrillation, Polymerase Chain Reaction, Hyperglycaemia, Thromboembolism, Respiratory Distress

**DOI:** <https://doi.org/10.47391/JPMA.S6-ACSA-20>

<sup>1</sup>Ngimbang General Hospital, Lamongan, <sup>2,3</sup>Wates Husada General Hospital, Gresik, <sup>4</sup>Department of Cardiology & Vascular Medicine, Dr Soetomo General Hospital, Indonesia.

**Correspondence:** Dimas Rio Balti **Email:** driobalti@gmail.com

**ORCID ID:** 0000-0003-2990-273X

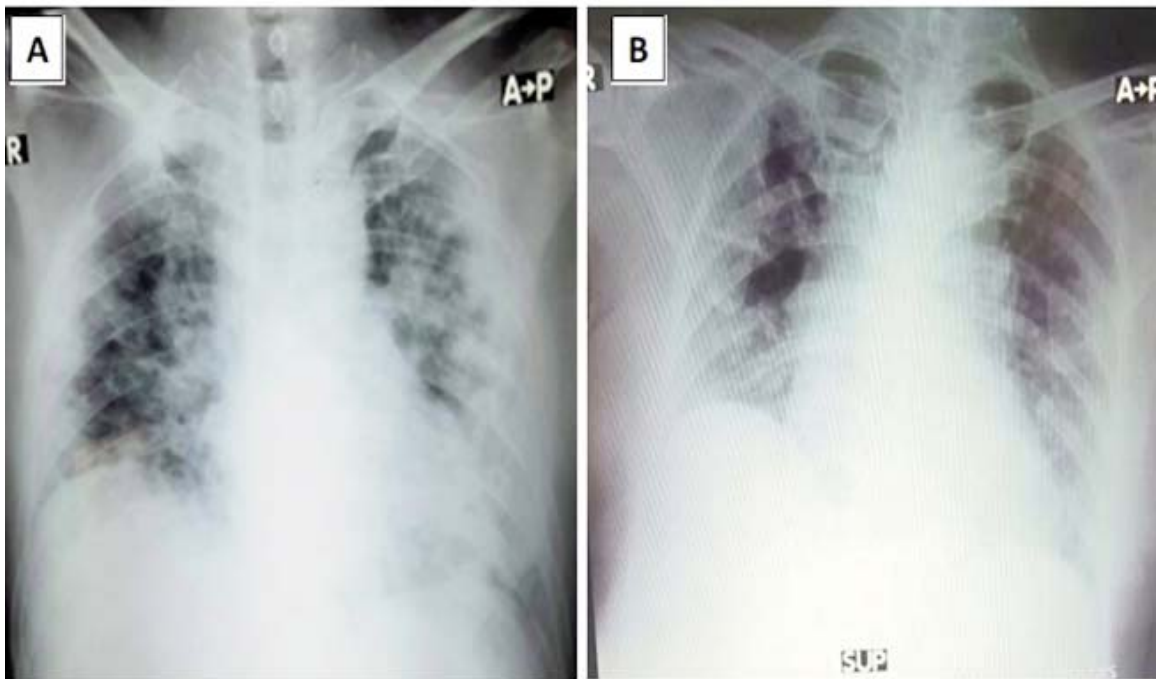
### Introduction

Some of the main problems in critically ill Coronavirus disease 2019 (COVID-19) cases are severe inflammatory response and hypercoagulable state, which often lead to acute respiratory distress syndrome (ARDS), cytokine storm, cardiac injury, Disseminated intravascular coagulation (DIC), venous thromboembolic (VTE), microthrombosis, and pulmonary embolism.<sup>1,2</sup> A recent systematic review and meta-analysis on available guidelines on thromboprophylaxis in COVID-19 patients, suggests, that in critically ill patients with COVID-19, anticoagulant thromboprophylaxis with Low Molecular Weight Heparin (LMWH) or Unfraction Heparin (UFH) is preferred over fondaparinux or a Direct Oral Anti Coagulant (DOAC).<sup>3</sup> Nevertheless, more affordable alternative treatment is needed because LMWH or UFH is not always feasible. DLBS1033, a serine protease extracted from the local earthworm (*Lumbricus rubellus*), is one of the oral fibrinolytic preparation that has been proven safe and effective in some cases of VTE such as Deep Vein Thrombosis (DVT).<sup>4</sup> However, its uses and effectiveness as an addition to the standard therapy for severe COVID-19 cases and hyper-coagulopathy are still not known. We report 2 cases where DLBS1033, was used as adjuvant therapy in severe COVID-19 patients in a limited-resource hospital.

### Case Reports

#### Case one

Mr. S, a 51 years old Indonesian male, was hospitalized at Ngimbang Hospital, Lamongan, East Java in October 2020, with severe COVID-19 infection. His chief complaint was fever, dyspnoea, and cough for the past 6 days. He had a history of uncontrolled hypertension (HT) and diabetes mellitus (DM). His vital signs were: Blood Pressure (BP) 170/110 mmHg, Heart Rate (HR) 81x/min irregular, Respiratory Rate (RR) 28 x/min, Temperature (T) 38.0 C, and room air SpO<sub>2</sub> 87%. There were coarse rales heard in both the lungs and bilateral oedema in lower extremities. Chest x-ray (CXR) showed bilateral lung infiltrate and cardiomegaly (CTR 65%) (Figure 1A). Electrocardiogram (ECG) examination revealed atrial



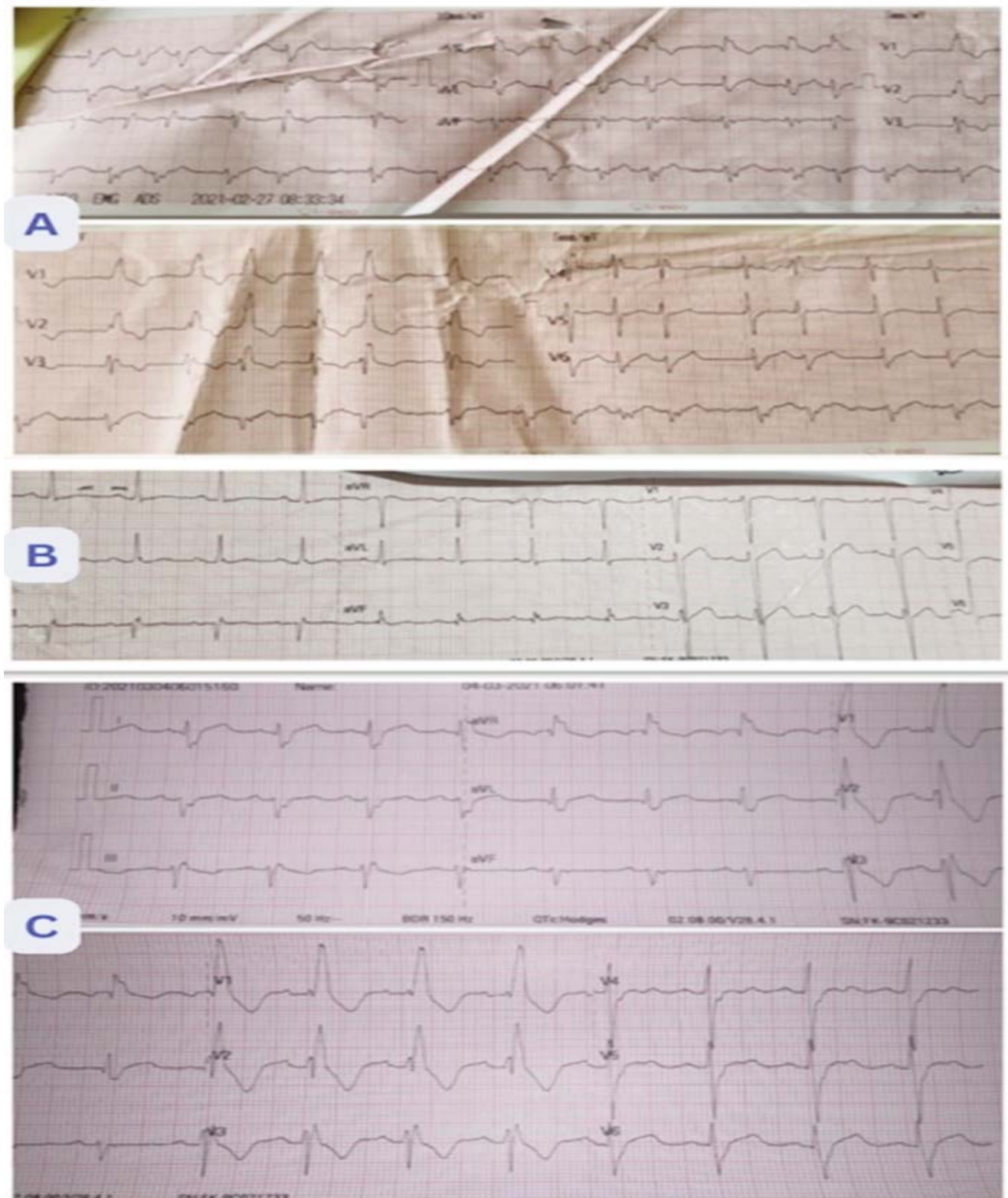
**Figure-1:** (A) CXR Mr.S on admission showed bilateral lung infiltrate and cardiomegaly (CTR 65%) (B) CXR Mrs. PS on admission showed bilateral lung infiltrates and cardiomegaly.

**Table-1:** Data patient comparison.

Identity	Mr. S / 51 y.o	Mrs P.S / 56 y.o
Comorbidity	ARDS + PH + HT + AF + HF + DM	ARDS + HT + DM + HF + CAD
Initial D-Dimer (ng/ml)	1074	1399
Treatment		
Initial Oxygen	Simple Mask 8 lpm	NRM 10 lpm
Antiviral	Remdesivir iv 100 mg o.d (10 days)	Remdesivir iv 100 mg o.d (10 days)
Antibiotics	Levofloxacin iv 750 mg o.d.(7 days)	Levofloxacin iv 750 mg o.d. ( 7 da7s)
Steroid IV	Hydrocortisone 100 mg iv	Dexamethasone 6 mv iv (7 days)
Vitamin D	5000 iu o.d	5000 iu o.d
Treatment	Long-acting insulin 24 iu o.d s.c Short-acting insulin 30 iu t.i.d s.c Trimetazidine 35 mg po b.i.d Furosemide 40 mg po o.d Spironolactone 25 mg o.d Amlodipin 10 mg o.d	Long-acting insulin 12 iu o.d s.c Short-acting inuslin I iu. t.i.d. s.c Trimetazidine 35 mg po b.i.d Bisoprolol 1,25 mg po o.d Spironolactone 12,5 mg o.d Amlodipin 10 mg o.d

brillation (AF) rhythm with ventricular response 75-120x/min, and right bundle branch block (RBBB) (Figure 2A). Echocardiography tracing was within normal limits without any thrombus and vegetation. Laboratory findings showed positive Polymerase Chain Reaction (PCR) of SARS-COV-2 infection, random blood glucose (RBG) 412 mg/dL (Ref <200 mg/dl), Fibrinogen 594

mg/dL(Ref 200-400 mg/dL), D-Dimer 1074 ng/mL (Ref <500 ng/mL), hs-CRP 84.7 mg/L (Ref <6 mg/L), PO<sub>2</sub>/FiO<sub>2</sub> ratio 250 (Ref 400-500), while other parameters were within normal limits. He was diagnosed with acute respiratory distress syndrome (ARDS), severe COVID-19 infection, suspected pulmonary hypertension (PH), HT, AF, heart failure (HF), DM, and hypercoagulopathy.



**Figure-2:** (A) ECG Mr. S on admission atrial fibrillation rhythm with ventricular response 75-120x/min, and RBBB (B) ECG Mrs. P on admission normal sinus rhythm and hypertrophy LVH (C) ECG Mr. S evaluation on the 4th day showed normal sinus rhythm with normal R-R interval and persistent RBBB.

### Case two

Mrs. PS, 56, was hospitalized with severe COVID-19 infection in Ngimbang Hospital, Lamongan, East Java on November 2020. Her chief complaint was fever and dyspnoea for 4 days which worsened a day before admission. She also felt chest discomfort. She had a history of uncontrolled HT and coronary artery disease (CAD). Her vital signs were BP 140/90, HR 112x/min regular, RR 26 x/min, Temp. 39,1 degree Celsius, and room air SPO<sub>2</sub> 88% at admission. There were coarse rales heard in both lung fields. CXR showed bilateral lung infiltrate and cardiomegaly (Figure 1B). ECG examination revealed normal sinus rhythm and left ventricular hypertrophy (LVH) (Figure 2B). Laboratory findings showed abnormal results with positive PCR of SARS-COV-2 infection, RBG 214 mg/dL, Fibrinogen 735 mg/dL, D-Dimer 1399 ng/mL FEU, Hs-CRP 189,4 mg/L, PaO<sub>2</sub>/FIO<sub>2</sub> ratio 123.3, and sodium 127 mEq/L. She was diagnosed with severe pneumonia COVID-19 infection with ARDS, hypertension, hyperglycaemia, hyper coagulopathy, heart failure, and CAD.

Both patients were admitted to the intensive care unit. They were both given oxygen supplementation and therapy for severe COVID-19 infection with antiviral, antibiotics, steroid iv, vitamin D, and therapy based on symptoms and comorbidity (Table 1). Thromboprophylaxis was planned for both of them due to their hypercoagulable state with high D-Dimer, however, heparin or LMWH were unavailable because of limited availability, thus fondaparinux 2.5 mg was given, added with DLBS1033, two enteric-coated caplets @490 mg t.i.d. for 10 days.

The symptoms and clinical condition gradually improved and the oxygen therapy could be tapered down on the 7<sup>th</sup>-9<sup>th</sup> day.

Mr. S' ECG also reverted to a normal sinus rhythm of 98 bpm with RBBB on the 4th Day (Figure 2C). Their serial laboratory findings showed a gradual improvement in 9 days with favourable outcomes in the inflammatory and coagulopathy parameters. It was observed that the D-Dimer of Mrs. PS had risen on the 9th day without any relevant symptoms (Table 2). No bleeding event was found. The patients were discharged on the 9<sup>th</sup> day in an asymptomatic status and stable haemodynamics with continuation of oral therapy for DM, HF, and HT at home. Oral anticoagulants as Rivaroxaban 20 mg o.d and DLBS1033 490 mg t.i.d. were given for 5 days. Regular follow-up a week later showed no residual symptoms with stable vital signs.

### Discussion

In these series, we reported 2 severe pneumonia cases with hypercoagulable (high fibrinogen, D-Dimer, and HsCRP at presentation). Both cases were treated with the standard supportive and medication therapy for severe COVID-19 infection according to the national guideline<sup>5</sup> with addition of thromboprophylaxis using Fondaparinux 2.5 mg s.c o.d and 2 caplets of DLBS1033 @ 490 mg t.i.d, which could be tolerated well in all patients without any adverse reactions of bleeding. This is corroborated by the safety and tolerability profile of DLBS1033 that had previously been demonstrated in healthy adult subjects in a double-blind randomized controlled trial over 14 days of treatment with DLBS1033, 490 mg 3 times daily for 14 days. The result showed no differences between DLBS1033 and placebo in terms of haematological parameters, blood chemistry parameters, urine test, stool occult blood, and ECG interpretation. There were no bleeding symptoms or allergic reactions found in this study.<sup>6</sup>

Lumbrokinase, which is the substance of DLBS1033, has properties to dissolve fibrin and activate plasminogen. A vitro study by Trisina et al<sup>7</sup> showed that this effect was acquired from its active substance serine protease enzyme group, which is known to have thrombolytic and fibrinogenolytic properties on fibrinogen, lowers blood viscosity, decreases platelet aggregation, prolongs clotting time, and degrades the thrombus.<sup>7</sup> A clinical trial on cerebral infarct subjects also proved that the mechanism of lumbrokinase as oral antithrombotic and fibrinolytic agent, is by inhibiting the coagulation intrinsic pathway and activating fibrinolytic pathway by increasing t-PA activity.<sup>8</sup> Another research by Kurnia et al showed that DLBS1033 has pleiotropic effects on vascular cell due to its anti-inflammatory property which was proven by its ability to down-regulate inflammatory biomarkers and reduce vascular smooth muscle cells proliferation and migration.<sup>9</sup>

The reduction of fibrinogen level and HsCRP level along a 9-day serial evaluation in our cases indicated that the combination of fondaparinux 2,5 mg s.c and DLBS1033 could have contributed to the degradation of micro-thrombosis and reduction of hypercoagulable state in our ARDS COVID-19 patients, adding to the overall effect of the other standard treatment to reduce the hyperinflammatory state. Meanwhile, the rebound D-dimer level seen on the 9<sup>th</sup> Day in the second case might result from the fibrinolytic activity on a larger thrombus.<sup>10</sup>

### Conclusion

Overall, our cases are the first two case reports of

lumbrokinase DLBS1033 in addition to fondaparinux for treating severe COVID-19 patients, as a thromboprophylaxis and treatment for hypercoagulable and hyperinflammatory state of ARDS patients in facilities with limited resources. The two patients in our hospital showed good clinical outcomes without any adverse effects of the drugs, however, further clinical trials are needed to provide more valid evidences.

**Consent for publication** of their case reports, was provided by both patients in the interest of promoting science.

**Disclaimer:** None.

**Conflict of Interest:** None.

**Funding disclosure:** None.

## References

1. Abou-Ismaïl MY, Diamond A, Kapoor S, Arafah Y, Nayak L. The hypercoagulable state in COVID-19: Incidence, pathophysiology, and management. *Thromb Res.* 2020;194:101-15.
2. Bhattacharyya R, Iyer P, Phua GC, Lee JH. The Interplay Between Coagulation and Inflammation Pathways in COVID-19-Associated Respiratory Failure: A Narrative Review. *Pulm Ther.* 2020;6(2):215-31.
3. Moores LK, Tritschler T, Brosnahan S, Carrier M, Collen JF, Doerschug K, et al. Prevention, Diagnosis, and Treatment of VTE in Patients With Coronavirus Disease 2019: CHEST Guideline and Expert Panel Report. *Chest.* 2020;158(3):1143-63.
4. Satuti AE, Hariawan H, Mumpuni H. Efficacy of Lumbrokinase and Warfarin Compared to Single Warfarin on Thrombus Resolution in Deep Vein Thrombosis. *Acta Cardiologia Indonesiana.* 2017;1(2).
5. Burhan E SA, Isbainiah F, Nasution SA, Ginanjar E, et al. Pedoman Tatalaksana COVID-19. EDITION-3, 2020.
6. Tjandrawinata RR, Yunaidi DA, Susanto LW. The Safety and Tolerability of Lumbrokinase DLBS1033 in Healthy Adult Subjects. *Drug Res.* 2016;66(6):293-9.
7. Trisina J, Sunardi F, Suhartono MT, Tjandrawinata RR. DLBS1033, A Protein Extract from *Lumbricus rubellus*, Possesses Antithrombotic and Thrombolytic Activities. *J Biotechnol Biomed.* 2011;2011:519652.
8. Jin L, Jin H, Zhang G, Xu G. Changes in coagulation and tissue plasminogen activator after the treatment of cerebral infarction with lumbrokinase. *Clin Hemorheol Microcirc.* 2000;23(2-4):213-8.
9. Kurnia F, Tjandrawinata R. Bioactive protein fraction DLBS1033 exerts its positive pleiotropic effects in the vascular cells via down regulation of gene expression. *Medicinus.* 2011;24:18-24.
10. Cakar MA, Gunduz H, Varim C, Ozdemir F, Vatan MB, Akdemir R. Correlation between D-dimer levels and coronary artery reperfusion in acute myocardial infarction patients after thrombolytic treatment. *Blood Coagul Fibrinolysis.* 2013;24(6):608-12.