

Retractable congestive heart failure due to sinus valsalva rupture with coexisting gerbode defect: a rare case report

Bestya Presidiana¹, Anudya Kartika Ratri², Ririn Ramli³, Andrianto⁴, Arief Rakhman Hakim⁵

Abstract

Sinus of Valsalva aneurysm (SoVA) is a rare disease with less than 1% prevalence in the population. Most cases are asymptomatic, however, significant clinical manifestations are possible due to fistula formation and sudden rupture resulting in cardiac shunt. Eventually it may develop into progressive heart failure with high morbidity.

We report the case of a 33 year old female patient who presented with shortness of breath, ascites, and recurring hospitalisation. The cardiac examination revealed sinus tachycardia along with loud and continuous murmurs on the left parasternal border. Several standard diagnostic procedures could not be performed due to malignant arrhythmia in supine position. Echocardiography examination revealed SoV rupture with a gerbode defect, which was the underlying cause of severe retractable heart failure.

Keywords: Sinus of Valsalva Aneurysm, Supine Position, Aortic Aneurysm, Heart Septal, Ventricular, Heart Murmurs, Fistula, Arrhythmias, Cardiac, Dyspnoea, Tachycardia

DOI: <https://doi.org/10.47391/JPMA.S6-ACSA-12>

Introduction

Sinus of Valsalva aneurysm (SoVA) is a rare structural venous disorder with less than 1% prevalence in the general population. Its frequency is known to be five times higher amongst Asians compared to Caucasian population¹. SoVA is often asymptomatic and mostly diagnosed by coincidence during unrelated imaging, surgery, or autopsy^{1,2}. Rupture or fistulae of SoVA may abruptly cause a shunt both in patients with the history of previous infection or not, such as endocarditis or syphilis.

¹⁻⁴Department of Cardiology & Vascular Medicine, Dr Soetomo General Hospital, ⁵Paediatric Division, Department of Cardiothoracic and Vascular Surgery, Universitas Airlangga, Dr. Soetomo General Hospital, Surabaya, Indonesia.

Correspondence: Bestya Presidiana.

Email: bestyapresidiana20@gmail.com

ORCID ID: >>>

Gerbode defect is an abnormal shunting between the left ventricle and the right atrium. It may also occur with a coexisting cardiac lesion, especially VSD or aortic regurgitation³. Due to its rare prevalence, SoVA or its rupture might be potentially misdiagnosed and left untreated.

Case Report

A 33-year-old female was referred to the ER of Dr. Soetomo general hospital Surabaya, in January 2021 with the main complaint of shortness of breath since 10 days. Her symptoms were relieved by taking a sitting position and aggravated during daily activities. The patient developed classic signs of fluid retention: ascites permagna, low appetite and calf swelling which resolved with furosemide. She also experienced intermittent palpitations. She was diagnosed with heart failure and structural heart disease ever since her first symptoms developed 4 years ago. Later, she was advised a surgical procedure, which she declined and has also been irregular with her intake of medication. During the preceding 2 months, she had been re-hospitalized three times and finally decided to get definitive management.

She was brought to our emergency department (ED), with blood pressure of 100/40 mmHg, with irregular heart rate of 90 bpm, respiratory rate 22-breaths per minute, and oxygen saturation of 97% in room air. Continuous murmur was heard in systolic phase, with punctum maximum on the left parasternal border ICS IV. The electrocardiogram showed atrial fibrillation with a moderate ventricular response and an inverted T in leads II, II, and aVF. The eGFR was low (15 ml/min/1.73m²). Physical examination also revealed jugular venous distention, bilateral rales, ascites permagna, and bilateral calf swelling.

Thorax PA X-ray showed cardiomegaly (CTR : 85%) with a sloping left heart edge and enlargement of the right cardiac silhouette.

Transthoracic echocardiography was subsequently performed and revealed normal LV function, concentric hypertrophy, and paradoxical normokinetic left

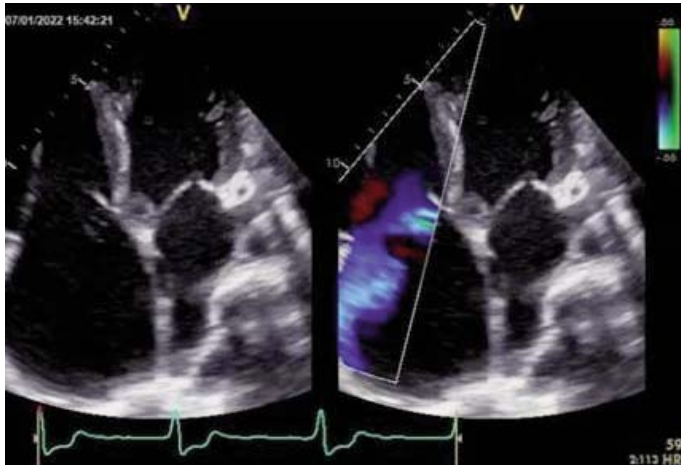


Figure-1: Apical four chambers view of transthoracic echocardiogram showing ruptured sinus of Valsalva aneurysm.

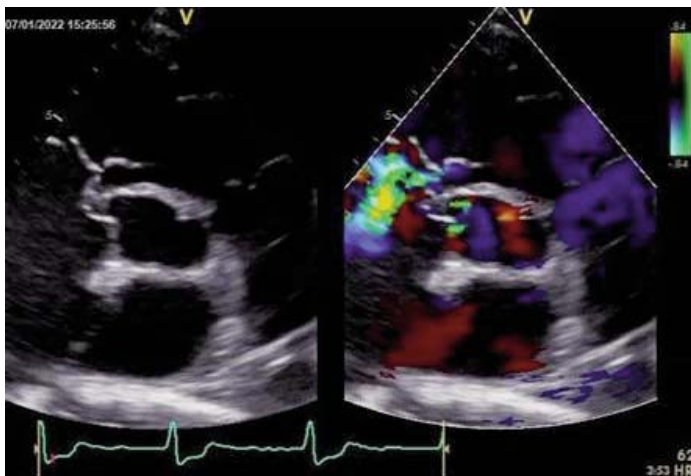


Figure-2: Parasternal short axis view of transthoracic echocardiogram showing ruptured sinus of Valsalva aneurysm.

ventricular movement. In addition, a small saccular aneurysm of right coronary sinus was seen which extended into the junction between RA, suggesting a SoV rupture with a Gerbode defect (Figure 1). The Aorta was observed to be bicuspid instead of a tricuspid basis. Moreover, there was mild aortic regurgitation, moderate tricuspid regurgitation, normal RV systolic function (TAPSE 1.4) with RA and RV dilatation, moderate pulmonary regurgitation, and a high probability of pulmonary hypertension. However, trans-oesophageal echocardiography could not be performed because of moderate palpitation, dyspnoea, dizziness, and bigeminy PVC in each supine position, even in the absence of electrolyte imbalance. Nonetheless, the transthoracic result was quite enlightening.

Considering the rupture of the aneurysm, an urgent repair was planned subsequent to her congestion being resolved. She was monitored very carefully with daily fluid intake reduction, adequate furosemide administration, and central venous catheter access for potassium electrolyte control management. In addition, the heart team decided to optimize her congestion state in the intensive care unit pre-operatively.

Open heart surgery revealed 2 points of SoV rupture, in size of 1,2 cm and 1 cm, respectively (figure 2). There was also an exhibit on Gerbode VSD under SoV. The defect had been closed by patches. The tricuspid annulus dilatation was repaired by the deVega procedure, which was application of the tricuspid annulus from the anteroseptal to the posteroseptal commissure using continuous sutures over pledges (Figure 3).

Two weeks after the surgery, the symptoms had diminished. Transthoracic echocardiography showed the

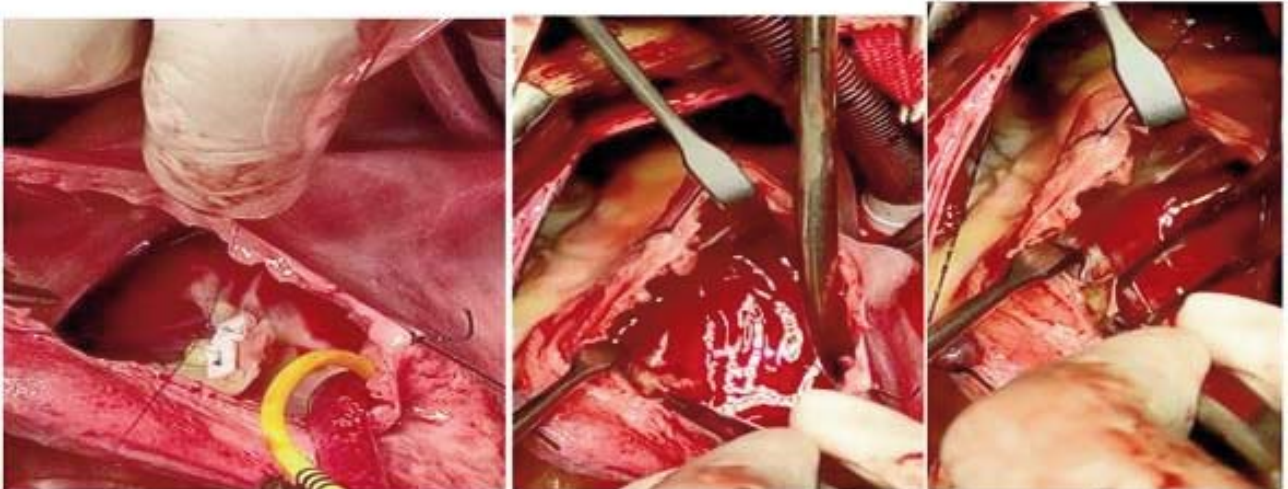


Figure-3: Right atrial view and repair of ruptured sinus of Valsalva aneurysm without signs of infection.

shrinking of the right heart. The rupture had been closed with minimal residual flow.

Discussion

The symptoms of shortness of breath precipitated by daily activities, ascites, and calf oedema typically result from a defect in the right heart including SoV rupture and fistule. Statistically, connections into the right atrium are reported in 39% and the right ventricle in 34% of the cases. Overflows onto the right heart causes hypotension and conduction disorders such as complete heart block and AF^{1,2}. Moreover, VSD and pericardial effusion may worsen the dyspnoea. The patient's cardiac examination revealed a VSD, but a coloured Doppler failed to establish a specific origin of the shunt whether it was associated with the opening of SoVA adjacent to the tricuspid valve or due to a limitation of the interference area⁴.

The distinction between SoV rupture and VSD is crucial to determine for the further management. A Gerbode VSD can also result in repetitive congestion as an abnormal shunting between the LV and the right atrium.¹ On one hand due to the severe congestive state, some diagnostic tools that require a supine position, such as trans-oesophageal echocardiography, CMR, and cardiac catheterization angiography could not be performed. Some valvular abnormalities could be discovered. In younger patients (7%), aortic valve regurgitation can be found⁴. On the other hand, trans-oesophageal echocardiography provides greater accuracy. An anatomy anomaly will present through cardiac catheterization, multi-sliced cardiac CT, or CMR imaging^{1,2}.

Thirty percent of SoV rupture cases may be associated with infection, such as endocarditis or syphilis. Although, some cases are known without the presence of underlying infection as well as a late presentation of an undiagnosed aortic media congenital heart defect.^{2,4} Some cases could be attributed to iatrogenic injury, chest trauma, collagen vascular disorders, or connective tissue diseases, such as Marfan's and Ehlers-Danlos Syndromes. A SoVA may also coincidentally perform with a bicuspid aortic valve^{1,2,5}.

In embryonic development, the base of the distal bulbar septum should be split. When a splitting does not occur, a saccular or aneurysm between the aortic valve annulus and the sinotubular junction is made¹. The deficiency of normal classic tissue and underdeveloped bulbus cordis have also been associated with SoVA^{2,5}.

Due to sudden rupture, a mild or an asymptomatic SoVA may abruptly develop into unstable heart failure. This might be fatal, so both diagnostics and prompt treatment

are crucial². The treatment options are percutaneous and open surgical closures. AHA/American Guidelines on Thoracic Aortic Disease recommend closure for asymptomatic aneurysms with a diameter > 5.5 cm, or > 5 cm with bicuspid valves or > 4.5 cm through the surgical repair.⁶ Surgical intervention is preferable for symptomatic patients with malignant arrhythmias, ostial coronary artery occlusion, or RVOT disorder, and complicated lesions such as bicuspid aortic valve, larger defects, or multiple rupture sites and endocarditis. On the other hand, the percutaneous technique is the alternative for patients who are unable to undergo surgery^{1,5,7,8}. Clinical trials of percutaneous occlusion with long-term follow-up data are rare. Regardless of the procedure technique, the primary closure and patch installation should be at a precise point. Moreover, some coexisting valvular disease requires aortic root replacement, valve repair, and valve replacement^{2,5}. Based on clinical evaluation, closure shows a satisfactory excellent outcome with 90-95% of long-term survival rates of 20 years, with rare recurrence. Besides, patient with recent SoVA repair survival rate is approximately 3.9 years, and perioperative mortality rate is between 1.9 to 3.9%.⁹

Conclusion

Patients with SoVA rupture may be left undiagnosed with heart failure symptoms. Echocardiography of coronary sinus can visualize the SoVA rupture, thus, the early repair can be performed to improve patient outcomes. The presented case with a SoV rupture with a Gerbode defect was successfully treated with open heart surgery.

Consent: Written consent for publishing the case report was obtained from the patient.

Disclaimer: None.

Conflict of Interest: None.

Source of Funding: None.

References

- Weinreich M, Yu PJ, Trost B. Sinus of valsalva aneurysms: review of the literature and an update on management. *Clin Cardiol* 2015;38:185-9. doi: 10.1002/clc.22359.
- Duval JL, Ramsingh RA, Rahaman NC, Rampersad RD, Angelini GD, Teodori G. Rupture of sinus of Valsalva aneurysm: case report and review of contemporary literature. *Perfusion* 2021;36:883-6. doi: 10.1177/0267659120966915.
- Doost A, Craig JA, Soh SY. Acute rupture of a sinus of Valsalva aneurysm into the right atrium: a case report and a narrative review. *BMC Cardiovasc Disord* 2020;20:84. doi: 10.1186/s12872-020-01383-7.
- Morii Y, Morinaga H, Kato K, Hisagi M, Tanaka H. Ruptured Sinus of Valsalva Aneurysm in a Patient with a Ventricular Septal Defect Who Dropped Out of Lifelong Medical Follow-up. *Intern Med* 2024;63:829-32. doi: 10.2169/internalmedicine.1395-22.

5. Breatnach CR, Walsh KP. Ruptured Sinus of Valsalva Aneurysm and Gerbode Defects: Patient and Procedural Selection: the Key to Optimising Outcomes. *Curr Cardiol Rep* 2018;20:90. doi: 10.1007/s11886-018-1038-z.
 6. Bass D, Tivakaran VS. Sinus of Valsalva Aneurysm. Treasure Island, FL: StatPearls Publishing; 2024.
 7. Hiratzka LF, Bakris GL, Beckman JA, Bersin RM, Carr VF, Casey DE Jr, et al. 2010 ACCF/AHA/AATS/ACR/ASA/SCA/SCAI/SIR/STS/SVM guidelines for the diagnosis and management of patients with Thoracic Aortic Disease: a report of the American College of Cardiology Foundation/American Heart Association Task Force on Practice Guidelines, American Association for Thoracic Surgery, American College of Radiology, American Stroke Association, Society of Cardiovascular Anesthesiologists, Society for Cardiovascular Angiography and Interventions, Society of Interventional Radiology, Society of Thoracic Surgeons, and Society for Vascular Medicine. *Circulation* 2010;121:e266-369. doi: 10.1161/CIR.0b013e3181d4739e.
 8. Galeczka M, Glowacki J, Yashchuk N, Ditkivskyy I, Rojczyk D, Knop M, et al. Medium- and long-term follow-up of transcatheter closure of ruptured sinus of Valsalva aneurysm in Central Europe population. *J Cardiol* 2019;74:381-7. doi: 10.1016/j.jjcc.2019.03.012.
 9. Kuriakose EM, Bhatla P, McElhinney DB. Comparison of reported outcomes with percutaneous versus surgical closure of ruptured sinus of Valsalva aneurysm. *Am J Cardiol* 2015;115:392-8. doi: 10.1016/j.amjcard.2014.11.013.
-