

Surgical-orthodontic with atypical extraction pattern as a treatment for an anterior open bite: A case report

Abdurahman Alwadei

Abstract

This case report described the surgical-orthodontic interdisciplinary treatment of a patient with skeletal anterior open bite, class III skeletal pattern, steep mandibular plane, increased lower face height, and thin mandibular symphysis. The orthodontic preparation included an unusual extraction pattern (maxillary right first molar, maxillary left second premolar, and mandibular right central incisor), combined with two-jaw surgery comprised of maxillary advancement and differential impaction, bilateral malarplasty augmentation and mandibular asymmetric bilateral sagittal split osteotomy setback. The follow-up of a rare complication of surgical hooks breakage during surgery is reported. Guided by 3-dimensional digital platforms, treatment planning and execution, resulted in a more balanced and proportionate face with functional occlusion, and the case stability is shown in a 32-month follow-up.

Keywords: CL III malocclusion, (AOB) anterior open bite, dentofacial deformity, orthognathic surgery, digital dentistry.

DOI: <https://doi.org/10.47391/JPMA.9365>

Introduction

Correction of anterior open bite (AOB) is challenging due to its multifactorial etiology and relapse rate.¹ Temporary skeletal anchorage devices are useful in managing complex cases, often without surgical intervention.² However, facial appearance remains a primary reason that makes surgical-orthodontic treatment the standard approach in cases with significant dentofacial deformity,³ especially with its impact on patients' psychological wellbeing.⁴ This case report describes the surgical-orthodontic treatment of a markedly hyperdivergent patient with skeletal class III (Table), AOB, and articulation impairment, highlighting atypical extraction approach and mechanics along with a rare surgical complication with long-term follow-up. Notably, it

illustrates a fully digitized computer-assisted planning, simulation, and execution for orthognathic surgery utilizing several 3-dimensional imaging and planning platforms such as, Invisalign®, Dolphin®, computed tomography, and virtual surgical planning (VSP) (Figures 1 and 2).

Case History

A 17-year-old African American girl presented to the orthodontic clinic at the University of Illinois at Chicago,

Table: Cephalometric Measurements Before Treatment, and After Treatment.

Measurement	A (Initial) Taken at Initial Visit (17 years 3 months)	B (Final) Taken at Debond Visit (19 years 8 months)	Difference (A-B)
SNA°	79.9	83.2	3.3
SNB°	81.0	81.1	0.1
ANB°	-1.1	2.1	3.2
SN-MP°	55.0	49.5	5.5
FMA°	43.3	39.1	4.2
UI TO NA mm	6.0	1.6	4.4
UI TO SN°	103.3	93.2	10.1
LI TO NB mm	4.0	3.1	0.9
LI TO MP°	60.6	70.9	10.3
U Lip to E-Line	-2.1	2	4.1
L Lip to E-Line	3.1	6	2.9
L 6-6 width mm	33	40.5	7.5
L 3-3 width mm	12.3	17.2	4.9

SNA, sella-nasion-A point; SNB, sella-nasion-B point; ANB, A point-nasion-B point; SN-MB, sella-nasion-mandibular plane; FMA, Frankfort-mandibular plane angle; UI, upper incisor; SN, sella-nasion; NA, nasion-A point; NB, nasion-B point; LI, lower incisor; U, upper; L, lower.

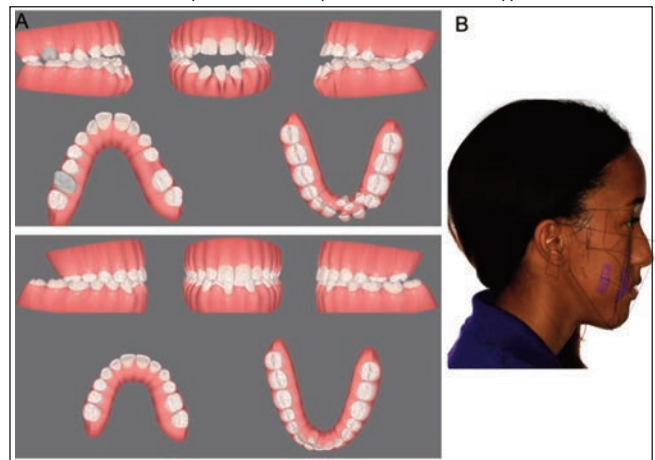


Figure-1: TA: Pretreatment digital simulation of teeth movement, and B: Visual treatment objective.

Department of Paediatric Dentistry and Orthodontics, College of Dentistry, King Saud University, Riyadh, Saudi Arabia.

Correspondence: Abdurahman Alwadei. e-mail: aalwadei@ksu.edu.sa
ORCID ID. 0000-0002-0408-6433

Submission complete: 27-03-2023

Review began: 11-05-2023

Acceptance: 21-10-2023

Review end: 09-09-2023

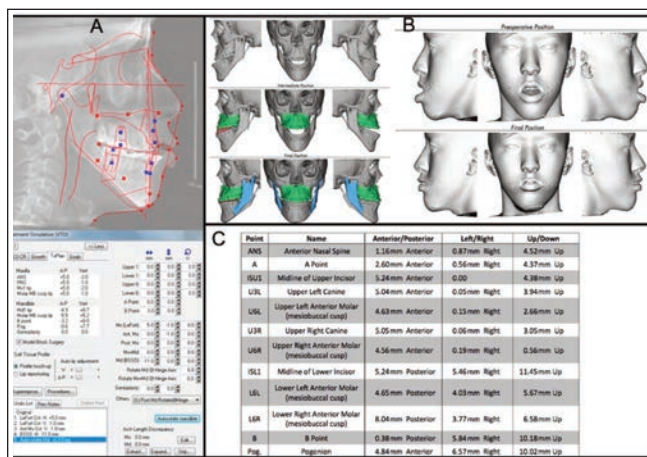


Figure-2: A and B: Preoperative virtual surgical plan, and C: Occlusal and bony anatomical landmarks and their summarized movements from preoperative position to simulated postoperative position.

College of Dentistry, United State, in January 22, 2014, with the chief complaint "I think I need surgery to fix my teeth". Her medical history was unremarkable. Facial analysis revealed concave profile, protrusive and deviated chin (to the left by ~3.5mm), hypoplastic malar region, protrusive and incompetent lips, increased incisal display at rest (~6mm). Around 80% of maxillary incisor display on "smiling" with the maxillary midline shifted to the left by 1mm (Figure 3).

Upon further analysis (Figures 3 and 4) the examination revealed defected restorations at teeth # 25,26,36,35, 31,41,45,46 & 47, severe caries was observed at teeth #17,16&27, along with a periapical radiolucency related to mandibular right central incisor, and erupted/erupting third molars. In the sagittal dimension, she had bilateral Class III molar relationship, 0 mm overjet, retroclined mandibular incisors, reverse curve of Spee. Vertically, she had an anterior open bite (8mm at maxillary right central incisor). Transversely, she had lingual crossbite at maxillary left second premolar and buccal crossbite at maxillary left second molar, and lingually tipped mandibular posterior teeth. She had tapered maxillary and mandibular arches with moderate maxillary crowding of 5mm and severe mandibular crowding of ~20.6mm. Bolton discrepancy was 2.5mm of mandibular anterior excess.

Assessment of temporomandibular joint indicated she did not have any signs or symptoms. No functional shift was detected, but adaptive tongue thrusting was observed. Skeletal analysis revealed a skeletal Class III pattern due to mild mandibular prognathism and maxillary hypoplasia, steep mandibular plane, increased lower face height, and stage five cervical vertebral maturation.

Guided by the VSP (Figure 2), the surgical-orthodontic treatment included a two-piece LeFort I maxillary

advancement osteotomy with differential impaction to correct the open bite and improve maxillary incisal display at rest and midface deficiency. Bilateral malarplasty augmentation for aesthetic purposes to improve her deficient malar bones, along with counterclockwise rotation of the mandible, and bilateral sagittal split osteotomy (BSSO) setback to correct the open bite and mandibular prognathism. The BSSO setback was performed asymmetrically to correct the mandibular asymmetry and midlines' discrepancy (Figure 2). Guided by the pre-treatment digital set-up (Figure 1), the extraction and planned teeth movement were as follow: 1) extraction of the roots of maxillary right first molar, maxillary left second premolar and close maxillary spaces via molars' protraction with moderate anchorage, 2) extraction of the mandibular right central incisors and align mandibular teeth, and 3) substitution of the mandibular left canine for mandibular left lateral incisor and mandibular left first premolar for mandibular left canine and allow for maxillary left canine to occlude between mandibular left first premolar and mandibular left second premolar.

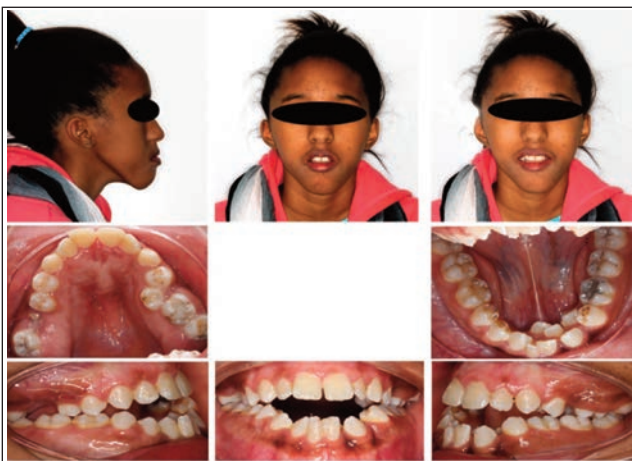

Figure-3: Pretreatment facial and intraoral photographs.

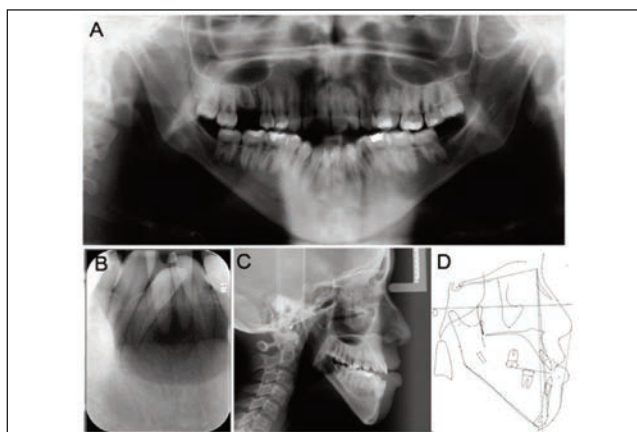


Figure-4: Pretreatment radiographs: A: panoramic radiograph, B: periapical radiograph, C: lateral cephalogram, and D: tracing.

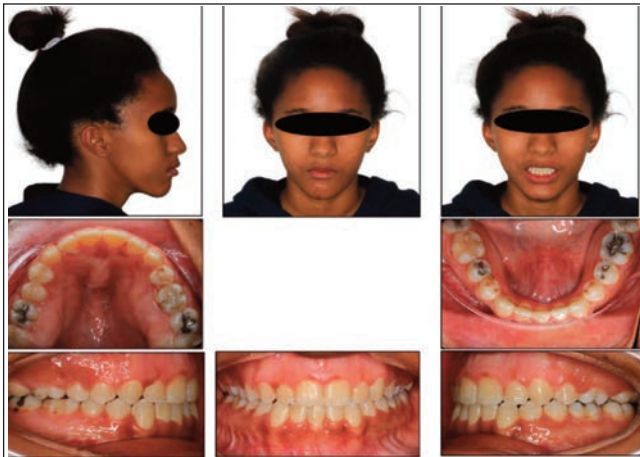

Figure-5: Posttreatment facial and intraoral photographs.

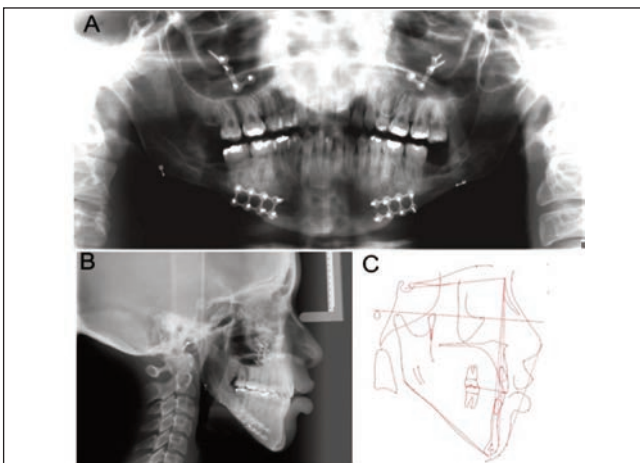


Figure-6: Posttreatment radiographs: A: panoramic radiograph, B: lateral cephalogram, and C: tracing.

The surgical procedure was performed after 17 months of active treatment. After 25 months of treatment, appliances were removed and the post-treatment records demonstrated that the interdisciplinary treatment was successful, and treatment objectives were achieved (Table 1 and Figures 5 and 6). The interdisciplinary team included a speech therapist who referred the patient for orthodontic treatment, a general dentist who restored her carious teeth and defective restorations, a periodontist who provided pre-orthodontic comprehensive evaluation, VSP technicians who co-simulated an optimal surgical plan and fabricated 3D printing splints, an oral surgeon, and an orthodontist. Posttreatment records show: 1) improvement in facial proportions, profile, mandibular symmetry, malar prominence, incisal display at rest, and lip posture and competency, and 2) optimal overbite, overjet, and posterior interdигitation despite the unusual extraction pattern. Although the surgery proceeded without any major complication, two hooks broke off and were retained near the inferior border of BSSO bilaterally (Figure 6-A&B).

Discussion

Patients who endure dentofacial deformities often experience challenges including low self-esteem and associated physiologic problems, impacting their overall quality of life.^{4,5} Because the excessive vertical discrepancy had the greatest negative impact on the patient's facial appearance, the need to perform maxillary impaction with bilateral malarplasty, as well as asymmetric BSSO mandibular setback and counterclockwise rotation was determined through patient-centered and interdisciplinary approach with the oral surgeon. This was achieved via detailed visually assisted consultation and continuous collaboration using cloud-based platforms (Figures 1 and 2). Therefore, the patient's main complaints and problems were addressed including excessive vertical discrepancy, incompetent and prominent lips, mandibular prognathism and asymmetry, concave profile, and midface deficiency. Nonetheless, the patient had a long lower facial height because of the mandibular hyper divergence but also due to the long chin. Genioplasty reduction would have helped to reduce the lower facial height and improve better lip competence, allowing for better lower lip draping with less mandibular incisor display. Verbal discussions with the oral surgeon during initial consultation entertained the idea of possible reduction genioplasty. However further imaging analysis, including the VSP indicated that the patient will undergo a complex surgery, including reduction genioplasty will be practically difficult and somewhat risky to accomplish given the patient's thin symphysis and the amount of planned counterclockwise rotation, and for this reason, genioplasty was not included in the VSP (Figure 2).

Facial beauty is a subjective concept influenced by cultural and ethnic factors. Furthermore, treatment planning and/or outcomes cannot be primarily or solely judged, based on cephalometric or facial normative values, which are helpful objective methods available for clinicians' diagnostic arsenals.⁶ Rather, treatment should be guided by combining clinical, facial, and soft tissue cephalometrics.⁶ For example, the patient's post-treatment skeletal vertical cephalometric values remained well-outside the normative values, but now she has a more balanced and proportionate face.

The long-term stability of treated skeletal AOB depends on different pretreatment, treatment, and posttreatment factors.⁷ Stability for this case is shown 32 months after debonding (Figure 5). There is an array of various complications associated with orthognathic surgery, which can be resolved without significant long-lasting problems via early identification of the cause and provision of proper treatment.⁸ Breakage of surgical orthodontic hooks (specifically) is an uncommon intra-operative complication

that has not been reported previously. It is recommended to ignore broken instruments and fragments, if the patient is asymptomatic and not at risk of infection but maintain close monitoring.⁹ Locating and retrieving a small foreign body can be challenging due to its accessibility and proximity to vital structures, as in the case of this patient, which can be potentially damaging upon retrieval.¹⁰ The surgeon identified the retained hooks on the panoramic radiograph, informed the patient/parents and discussed with them the pros and cons of a close monitoring approach versus retrieval. The surgeon and patient opted for close monitoring and the patient was examined regularly by the surgeon for over two years with no complications being encountered.

Conclusion

This case demonstrated the importance of interdisciplinary treatment planning and execution for a complicated malocclusion of skeletal origin. It also illustrated the utility of applying different digital platforms to provide a streamlined process throughout all stages of orthognathic treatment, with efficient communication as well as accurate, predictable, and safe treatment outcomes, which was reflected upon in this article, highlighting the discrepancies between the virtual surgical realm and actual surgical reality considering several factors such as function, esthetics, practicability, intra-operative complication, safety, and long-term stability.

Consent: The patient consented for publication of her case.

Disclaimer: None.

Conflict of interest: None.

Funding disclosure: None.

Abbreviations: AOB, anterior open bite; VSP, virtual surgical planning; BSSO, bilateral sagittal split osteotomy.

References

1. Wang M, Zhang B, Li L, Zhai M, Wang Z, Wei F. Vertical stability of different orthognathic treatments for correcting skeletal anterior open bite: a systematic review and meta-analysis. *Eur J Orthod* 2022;44:1-10. doi: 10.1093/ejo/cjab011.
2. González Espinosa D, de Oliveira Moreira PE, da Sousa AS, Flores-Mir C, Normando D. Stability of anterior open bite treatment with molar intrusion using skeletal anchorage: a systematic review and meta-analysis. *Prog Orthod* 2020;21:35. doi: 10.1186/s40510-020-00328-2.
3. Malara P, Bierbaum S, Malara B. Outcomes and Stability of Anterior Open Bite Treatment with Skeletal Anchorage in Non-Growing Patients and Adults Compared to the Results of Orthognathic Surgery Procedures: A Systematic Review. *J Clin Med* 2021;10:5682. doi: 10.3390/jcm10235682.
4. Belusic Gobic M, Kralj M, Harmicar D, Cerovic R, Mady Maricic B, Spalj S. Dentofacial deformity and orthognathic surgery: Influence on self-esteem and aspects of quality of life. *J Craniomaxillofac Surg* 2021;49:277-81. doi: 10.1016/j.jcms.2021.01.024.
5. Vongkamolchoon S, Sinha SP, Liao YF, Chen YR, Huang CS. The impact of a surgery-first approach on oral health-related quality of life. *Int J Oral Maxillofac Surg* 2021;50:1336-41. doi: 10.1016/j.ijom.2021.02.010.
6. Alkhayer A, Piffkó J, Lippold C, Segatto E. Accuracy of virtual planning in orthognathic surgery: a systematic review. *Head Face Med* 2020;16:34. doi: 10.1186/s13005-020-00250-2.
7. Al-Thomali Y, Basha S, Mohamed RN. The Factors Affecting Long-Term Stability in Anterior Open-Bite Correction - A Systematic Review. *Turk J Orthod* 2017;30:21-7. doi: 10.5152/TurkJOrthod.2017.010.
8. Kim YK. Complications associated with orthognathic surgery. *J Korean As-soc Oral Maxillofac Surg* 2017;43:3-15. doi: 10.5125/jkaoms.2017.43.1.3.
9. Sukegawa S, Kanno T, Shibata A, Matsumoto K, Sukegawa-Takahashi Y, Sakaida K, et al. Use of an intraoperative navigation system for retrieving a broken dental instrument in the mandible: a case report. *J Med Case Rep* 2017;11:14. doi: 10.1186/s13256-016-1182-2.
10. Gandevala A, Parekh B, Poplai G, Sayed A. Surgical removal of fractured endodontic instrument in the periapex of mandibular first molar. *J Int Oral Health* 2014;6:85-8.

Author Contribution:

ARA: Carried out all aspects of the study and writing the manuscript