

Leukocyte adhesion defect: An uncommon immunodeficiency

Sehar Nigar, Ejaz Ahmed Khan, Tahir Aziz Ahmad

Abstract

Leukocyte adhesion deficiency (LAD) is a rare primary immunodeficiency disorder with autosomal recessive inheritance which is characterized by presence of a defect of phagocytic function resulting from a lack of leukocyte cell surface expression of $\beta 2$ integrin molecules (CD11 and CD18) that are essential for chemotaxis. The classic symptoms of the disease are failure of separation of the umbilical cord and recurrent bacterial infections, which continue throughout life.

We describe here two cases of infants who presented with characteristic history of recurrent infections, delayed separation of umbilical cord and marked leukocytosis.

Keywords: Leukocyte adhesion defect.

Introduction

Three leukocyte adhesion deficiency (LAD) disorders have been well recognized, caused by genetic defects in Beta 2 integrin family consist of LFA-1 (CD11a/CD18), Mac-1 (CD11b/CD18), Complement receptor 4 (CD11c/CD18), and (CD11d/CD18).¹

LAD-I is caused by mutations in the ITGB2 gene coding $\beta 2$ subunit of beta 2 integrin family. This mutation results in formation of $\beta 2$ subunit that cannot bind with other subunits to form $\beta 2$ integrin. Leukocytes that lack these integrin fail to attach to blood vessel wall to contribute in immune response.¹

LAD-II is a rare disorder characterized by deficiency in a guanosine diphosphate-fucose transporter in the Golgi apparatus, which is essential for fucosylating the ligands of the selectin adhesion receptors.^{4,5} Thus leukocytes fail to roll along the vasculature and integrin-mediated adhesion stabilization does not take place.²

LAD-III, the most recently described type in which the integrins on bone marrow-derived leukocytes and platelets fail to function due to mutation in the FERMT3 gene coding for the kindlin-3 protein, thus introducing a premature stop codon resulting in a non-functioning protein.^{3,4}

.....
Shifa International Hospital, Islamabad.

Correspondence: Ejaz Ahmed Khan. Email: ejazkhan99@hotmail.com

Case-1

An 8 months old female child was brought to Shifa International Hospital in January 2016, with history of fever, and cough for 3 days. Fever was high grade, associated with vomiting and loose stools. Vomiting was non greenish, non-projectile, and loose stools were semi solid and greenish in colour, not associated with runny nose and runny eyes. She had multiple episodes of pyrexia from the age of 2 months, every 3-4 weeks that required multiple hospitalizations. She was the only child of consanguineous parents born at term by spontaneous vaginal delivery following an uncomplicated pregnancy. The umbilical cord separated on 41st postnatal day. There was no history suggestive of sepsis or umbilical infection in the neonatal period. She was developmentally normal and received her routine immunizations.

On examination, she had no dysmorphism, was pale, febrile with no icterus, petechiae, or bruises. Vitals were normal. Her weight was 7500 gram and height was 67 cm. There was no lymphadenopathy. Throat was congested with no exudates. Chest examination showed bilateral equal air entry with mild crepitation. Abdominal, cardiovascular and nervous examination all was unremarkable.

Investigations revealed haemoglobin concentration of 8.5 g/dl, platelet count of 556,000/mm³ markedly raised leukocyte count of 54000/mm³ (neutrophils 80%, lymphocytes 13%, and monocytes 7%). Chest x-ray showed bilateral infiltrates. Her serum immunoglobulin profile and flow cytometry analysis revealed diagnosis of LAD 1 type (Figure-1).

The child was managed with antibiotics and discharged on trimethoprim/ sulfamethoxazole and fluconazole prophylaxis. Since the day of discharge she had no follow-up.

Case-2

A three and half months old male child was brought to Shifa International Hospital in 2015, with history of fever for 4-5 days. Fever was high grade, associated with cough. There was no history of vomiting, loose stools, runny nose and runny eyes. He was the third child of consanguineous parents born at term by spontaneous vaginal delivery

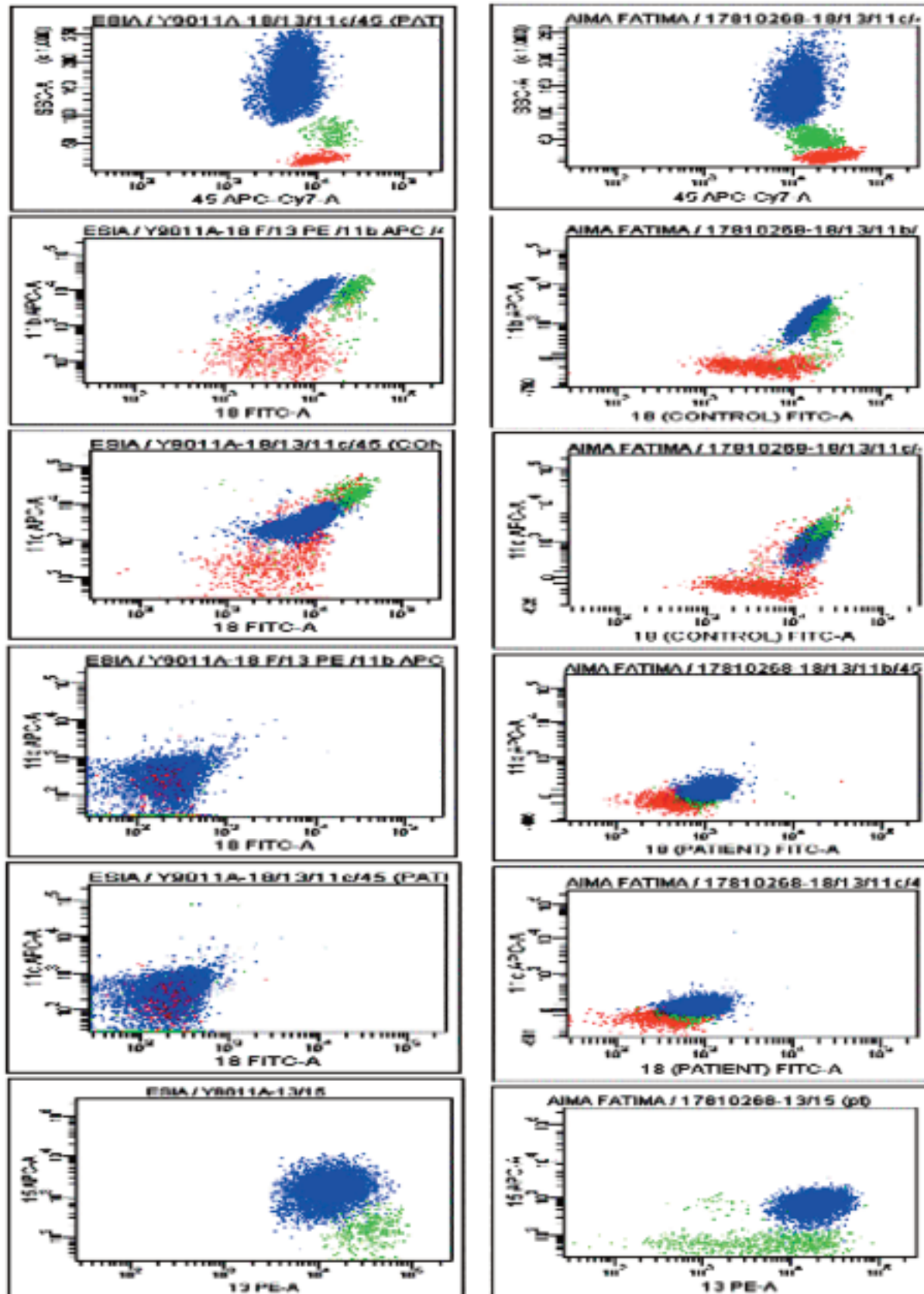


Figure-1 & 2: Analysis of the single cell suspension prepared from peripheral blood reveals complete deficiency of CD18, CD11b and CD11c on patients white blood cells.

Table: Laboratory results of both cases.

Reports	Case 1	Case 2	Reference Values
Hemoglobin (g/dl)	8.5	8.1	16-Nov
Leukocytes count/microliter	54000 N = 80% , L = 13%	87400 N = 86% , L = 10%	4000-11000
Platelets/UL	556000	611000	150,000 - 400,000
IgA g/L	1.03	0.1	0.08-0.91
IgG g/L	10.7	8.5	2.03-9.48
IgM g/L	2.83	0.97	0.17-1.50
Flow cytometry	Absence of CD 18, CD 11b, CD 11c	Absence of CD 18, CD 11b, CD 11c	

following an uncomplicated pregnancy. The umbilical cord separated on 22nd postnatal day. There was history of omphalitis in neonatal period. He was developmentally normal. One of his siblings died in infancy due to recurrent infections, while other siblings are healthy.

On examination, he was pale, febrile with no dysmorphism. His weight was 3600 gram which was below 5th percentile and height was 58 cm. Vitals were normal. There was no icterus, petechiae, or bruises or lymphadenopathy. Chest examination showed bilateral equal air entry. Abdomen was soft, slightly distended with liver 3 cm below right costal margin, soft in consistency, non-tender with smooth surface. There was no ascites and bowel sounds were audible. Cardiovascular and nervous system examination was unremarkable.

Investigations revealed haemoglobin concentration of 8.1 g/dl, platelet count of 611,000/mm³, markedly raised leukocyte count of 87400/mm³ (neutrophils 86%, lymphocytes 10%, monocytes 3%). Blood culture did not yield any organism. Serum immunoglobulins levels were normal for age. Flow cytometry was done (Figure-2). Based on his clinical presentation, family history and flow cytometric analysis, the diagnosis of LAD type 1 was established. Since the time of diagnosis, he had 2-3 times hospitalization for oral ulcer, otitis media, fungal infection and fevers. Bone marrow transplant has not been done yet, due to non-availability of donor.

Verbal consent was taken from father on telephone for publication of the case.

Discussion

Leukocyte adhesion deficiency type I (LAD-1) is an autosomal recessive disorder characterized by severe and recurrent bacterial infections, altered wound healing and significant morbidity that is caused by absent or diminished expression of integrins $\beta 2$ class.⁶

In severely deficient $\beta 2$ expression (less than 1% of the normal amount of cell surface expression of the $\beta 2$

integrin heterodimers) patients often die within the first year while moderately deficient $\beta 2$ expression (5%-10% of the normal level) results in a milder form of disease.⁷ The cardinal features of classical form of disease includes delayed detachment of umbilical cord, non-purulent bacterial infections in the presence of marked granulocytosis and impaired wound healing.⁸ Both cases presented had these classical features.

The umbilical cord usually sloughs by the end of 2nd week of life and mean time of separation is 7.4 days. However causes of delayed separation of cord such as urachal anomalies, antibiotic administration, prematurity and low birth weight must be excluded.^{11,12}

In our cases, both infants had the characteristic clinical features of delayed separation of cord, recurrent infections and marked leukocytosis. With suspicion of LAD it was decided to investigate it and diagnosis was confirmed by flow cytometry showing absence of CD18, CD11b, CD11c on neutrophils. Over 300 cases of LAD 1 have been reported worldwide, while for LAD II and LAD III, there are less than 10 cases each.⁵ Tipu et al have reported a patient to be suffering from this disease from Pakistan.⁵

LAD is an attractive disease for human gene therapy as the conventional therapy with antibiotics and granulocytes transfusions improves the symptoms only but does not correct the phenotype.¹⁰ The only definite treatment is stem cell or bone marrow transplantation from histocompatible relatives and should be considered as an early therapeutic option if a suitable HLA-matched stem-cell donation is available.⁹ Our cases emphasize that as physicians we should investigate any child presenting with delayed umbilical cord separation and markedly raised leukocyte count. Detail immunological assessment is also needed with management aimed at treating infections, hygiene, and antibiotic prophylaxis with age appropriate immunizations. Definite therapy requires stem cell transplant or gene therapy that should be

explored early.

Conclusion

LAD is a rare immune deficiency disorder and should be suspected in an infant with typical presentation and confirmed by flow cytometric analysis for the expression of deficient integrin molecules on leukocytes.

Disclaimer: The abstract has not been published or presented in any conference.

Conflict of Interest: None.

Funding Sources: None.

References

1. van de Vijver E, Maddalena A, Sanal Ö, Holland SM, Uzel G, Madkaikar M, et al. Hematologically important mutations: leukocyte adhesion deficiency (first update). *Blood Cells Mol Dis*. 2012; 48:53-61.
2. Simpson BN, Hogg N, Svensson LM, McDowall A, Daley W, Yarbrough K. A New Leukocyte Hyper adhesion Syndrome of Delayed Cord Separation, Skin Infection, and Nephrosis. *Pediatrics*. 2014; 133: e257-62.
3. Svensson L, Howarth K, McDowall A, Patzak I, Evans R, Ussar S, et al. Leukocyte adhesion deficiency-III is caused by mutations in KINDLIN3 affecting integrin activation. *Nat Med*. 2009; 15: 306-12.
4. Malinin NL, Zhang L, Choi J, Ciocea A, Razorenova O, Ma YQ, et al. A point mutation in KINDLIN3 ablates activation of three integrin subfamilies in humans. *Nat Med*. 2009; 15: 313-8.
5. Tipu HN, Tahir A, Ahmed TA, Hazir T, Waqar MA. Leukocyte Adhesion Defect. *J Pak Med Assoc*. 2008; 58: 643-5.
6. Harris ES, Shigeoka AO, Li W, Adams RH, Prescott SM, McIntyre TM, et al. A novel syndrome of variant leukocyte adhesion deficiency involving defects in adhesion mediated by beta1 and beta2 integrins. *Blood*. 2001; 97: 767-76.
7. Gallin JI, Snyderman RK, Ishimoto TK, Baldwin ET, Anderson DC, Gallin JI, Snyderman R. The role of beta2 integrins in inflammation. *Inflammation: Basic Principles and Clinical Correlates*. 3rd ed. Philadelphia: Williams and Wilkins, 1999; pp- 537-69.
8. Kuijpers TW, Van Lier RA, Hamann D, de Boer M, Thung LY, Weening RS, et al. Leukocyte adhesion deficiency type 1 (LAD-1)/variant. A novel immunodeficiency syndrome characterized by dysfunctional beta2 integrins. *J Clin Invest*. 1997; 100: 1725-33.
9. Waseem Qasim, Marina Cavazzana-Calvo, E. Graham Davies, Jeffery Davis, Michel Duval, et al. Allogeneic Hematopoietic Stem-Cell Transplantation for Leukocyte Adhesion Deficiency. *Pediatrics*. 2009; 123: 836-40.
10. Movahedi M, Entezari N, Pourpak Z, Mamishi S, Chavoshzadeh Z, Gharagozlou M, et al. Clinical and Laboratory Findings in Iranian Patients with Leukocyte Adhesion Deficiency. *J Clin Immunol*. 2007; 27: 302-7.
11. Kliegman RM, Stoll BJ. The fetus and the neonatal infant. In: Behrman RE, Kliegman RM, Jenson HB, eds. *Nelson Textbook of Pediatrics* 16th ed. Philadelphia: WB Saunders, 2000; pp-257.
12. Razvi S, Murphy R, Shlasko E, Cunningham-Rundles C. delayed separation of the umbilical cord attributable to urachal anomalies. *Pediatrics*. 2001; 108: 493-4.