

Suprachoroidal silicone oil migration following 27 gauge 3 ports pars plana vitrectomy – a rare complication and its management

Fiza Shaheen,¹ Sahar Fatima,² Hashim Ali Khan,³ Muhammad Amer Awan⁴

Abstract

Suprachoroidal silicone oil migration is an unusual complication of small gauge 3 ports Pars plana vitrectomy (3PPV) system. Our objective is to report a retrospective, observational case of an intra-operative suprachoroidal silicone oil (SO) migration during 27 gauge 3PPV and its successful surgical management. A 49 years old male patient with type 2 diabetes, presented to the ophthalmology outpatient department with reduced visual acuity in his right eye. He was diagnosed as having tractional retinal detachment involving macula. During combined phaco-vitrectomy following injection of SO, peripheral choroidal elevations were noted suggesting suprachoroidal SO migration. In an attempt to drain this intra-operatively nasal sclerotomy was enlarged. Post-operative B scan showed significant choroidal detachment for which patient was re-scheduled for surgery after 1 day. Three radial trans-scleral incisions (2 nasal and 1 temporal) for drainage were made at the site of maximum choroidal detachment. By massaging and widening these scleral incisions, suprachoroidal haemorrhage and SO was successfully drained with good post-operative visual improvement.

Keywords: Phacoemulsification, Retinal Detachment, Vitrectomy, Silicone oils, Choroidal Effusions, Choroid.

DOI: 10.47391/JPMA.6823

Submission completion date: 06-05-2022

Acceptance date: 04-01-2023

Introduction

Silicone oil (SO) since the 1960s has been a frequently used tamponade agent following retinal detachment surgery¹. Although rare, complications of silicone oil migration includes migration into lateral ventricles of the

¹Department of Ophthalmology, Al-Shifa Trust Eye Hospital, Islamabad, Pakistan, ²Department of Ophthalmology, Shifa College of Medicine, Islamabad, Pakistan, ³Department of Ophthalmology, SEHHAT Foundation Hospital, Danyor, Pakistan, ⁴Department of Ophthalmology, Shifa International Hospital, Islamabad, Pakistan.

Correspondence: Muhammad Amer Awan.

Email: dramer_awan@yahoo.co.uk

ORCID ID. 0000-0002-0043-1930

brain², eyelid³, subconjunctival space and orbit⁴, sub-retinal space⁵ and suprachoroidal space⁶ have occasionally been recorded in the literature. Among the smaller gauge vitrectomy systems, 27 gauge (G) pars plana vitrectomy (PPV) system since its establishment in 2010⁷ has been favoured by many ophthalmologists from all over the world. According to our knowledge this is the first case of intra-operative suprachoroidal SO migration during 27G 3PPV with successful surgical management resulting in a good post-operative visual recovery.

Case Report

A 49 years old male, a known case of type 2 diabetes mellitus underwent combined phacoemulsification cataract surgery with lens implant and 27G+ 3PPV, delamination, inner limiting membrane peel, endolaser and 1300 centistokes (cST) SO tamponade for diabetic tractional retinal detachment involving macula in his right eye (RE), at the Ophthalmology Department of Shifa International Hospital, Islamabad in March 2021. Pre-operative visual acuity (VA) in his RE was 0.50 logMAR (20/63 Snellen's equivalent). Unfortunately, during the operation, 27G viscous fluid injection (VFI) cannula was commercially unavailable, so 27G trocar was removed and 23G VFI cannula was utilized to inject SO without trocar. During air/SO exchange, peripheral choroidal elevation was noted both nasally and temporally. SO injection was immediately stopped as soon as suprachoroidal SO migration was recognized. (Figure 1). This occurred possibly due to incorrect positioning of VFI

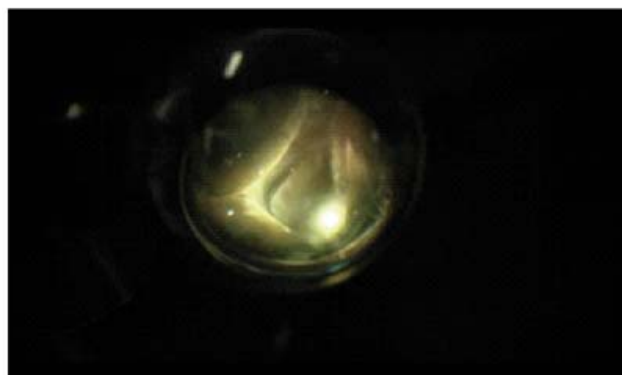


Figure-1: Figure showing intra-operative suprachoroidal silicone oil migration causing choroidal detachment.

cannula within the suprachoroidal space.

An attempt to remove suprachoroidal migrated SO was made at the time of its recognition during the surgery through the enlargement of nasal sclerotomy. Surgery was concluded with intra-vitreous injection of SO. Post-operatively, there was no fundal view on first day due to retro-intraocular lens haemorrhage and suprachoroidal haemorrhage. Post-operative VA was hand movements with accurate light projection in all the 4 quadrants. B-scan ultrasonography was done which showed significant nasal and temporal choroidal detachment (due to the combination of both suprachoroidal haemorrhage and SO). Patient was then rescheduled for another surgery after two days. Initially anterior chamber maintainer was used with intraocular pressure of 60 mmHg. Three long radial trans-scleral incisions of 2mm (2 nasal and 1 temporal) were made at the site of maximum choroidal detachment for drainage. By massaging and widening the scleral incisions, most of the suprachoroidal haemorrhage and SO was successfully removed. This was followed by SO removal from the vitreous cavity using 25G 3PPV system via 25G VFI cannula. Perfluoro-carbon liquid (PFCL) was then injected into the cavity to displace the remaining suprachoroidal SO anteriorly which was then expelled out from the already made scleral incisions. These draining sclerotomies were sutured using 6/0 vicryl. PFCL air exchange was performed followed by 1300 cST SO injection. Post-operatively, VA was counting fingers in the operated eye on 1st day. Retina and choroid were in place with good SO fill. After 3 months SO was removed (Figure 2) and VA improved to 0.20 logMAR (20/32 Snellen's equivalent).

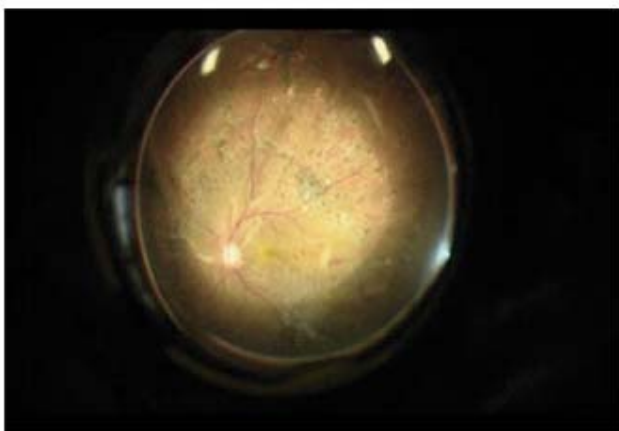


Figure-2: Fundus photos 3 months after removal of silicone oil

Discussion

Suprachoroidal SO migration is a rare complication that can lead to significant visual decline. Small Gauge

vitrectomy systems used for SO insertion although having many advantages including better control and ease in working closer to the retina, require a few surgical procedure modifications due to smaller width and flexibility of instruments during retinal surgeries⁸.

Unfortunately, no trocar was used during SO insertion and the length of the 23G VFI cannula is also relatively shorter. The exact mechanism of SO entrance into the suprachoroidal space is speculative. In our case, a possible mechanism could be incorrectly placed VFI cannula that initiated the passage of oil into the suprachoroidal space, but that would have become apparent during the early stages of the procedure. Under normal circumstances, hydrostatic pressure in the suprachoroidal space is equivalent to the intraocular pressure⁹. We believe that transient hypotony towards the end of the procedure could have led to choroidal detachment¹⁰, allowing the tip of the 23G VFI cannula to enter the suprachoroidal space. Hence, it is important to inject SO via using VFI cannula through trocar (25G or 23G) instead of directly injecting through a sclerotomy to prevent injecting SO into the suprachoroidal space in the instances where 27G 3PPV is performed. At the same time care should be taken in maintaining the position of the VFI cannula and to avoid hypotony. However using raised infusion pressure and making radial scleral incisions over maximum choroidal elevations, helped us to remove SO. PFCL injection was also instrumental in mobilising the remaining suprachoroidal SO anteriorly to get removed through scleral incisions.

In this case we successfully managed to drain SO from suprachoroidal space and achieved good visual outcome.

Conclusion

Migrated suprachoroidal SO is a rare complication following small gauge 3 PPV. Possible mechanism of migration could be an incorrectly placed cannula or choroidal detachment due to hypotony leading to the insertion of cannula into the suprachoroidal space. It can be successfully drained through the radial trans-scleral incisions made at appropriate sites with good post-operative visual prognosis.

Informed consent : Informed consent was obtained from the patient to publish his report along with the fundus photos.

Disclaimer: None.

Conflict of Interest: None.

Source of Funding: None.

References

1. Cibis PA, Becker B, Okun E, Cnaan S. The Use of Liquid Silicone in Retinal Detachment Surgery. *Arch Ophthalmol* 1962; 68: 590–9.
 2. Dong FT, Dai RP, Zheng L, Yu WH. Migration of intraocular silicone into the cerebral ventricles. *Am J Ophthalmol* 2005; 140: 156–8.
 3. Quintyn JC, Genevois O, Ranty ML, Retout A. Silicone oil migration in the eyelid after vitrectomy for retinal detachment. *Am J Ophthalmol* 2003; 136: 540–2.
 4. Nazemi PP, Chong LP, Varma R, Burnstine MA. Migration of intraocular silicone oil into the subconjunctival space and orbit through an Ahmed glaucoma valve. *Am J Ophthalmol* 2001; 132: 929–31.
 5. Dithmar S, Schuett F, Voelcker HE, Holz FG. Delayed sequential occurrence of perfluorodecalin and silicone oil in the subretinal space following retinal detachment surgery in the presence of an optic disc pit. *Arch Ophthalmol* 2004; 122: 409–11.
 6. Danylkova N, Gupta N, Jhaveri CD, Gill MK. Suprachoroidal silicone oil migration following retinal detachment repair. *Ophthalmic Surg Lasers Imaging Retina* 2013; 44: 284–6.
 7. Oshima Y, Wakabayashi T, Sato T, Ohji M, Tano Y. A 27-gauge instrument system for transconjunctival sutureless microincision vitrectomy surgery. *Ophthalmology* 2010; 117: 93–102.
 8. Nagpal M, Paranjpe G, Jain P, Videkar R. Advances in small-gauge vitrectomy. *Taiwan J Ophthalmol* 2012; 2: 6–12.
 9. Emi K, Pederson JE, Toris CB. Hydrostatic pressure of the suprachoroidal space. *Invest Ophthalmol Vis Sci* 1989; 30: 233–238.
 10. Zhang T, Wei Y, Zhang Z et al. Intraoperative choroidal detachment during small-gauge vitrectomy: analysis of causes, anatomic, and visual outcomes. *Eye* 2022 ; 36:1294-1301.
-