

Arteriovenous malformation of the prostatic median lobe: a rare case treated by transurethral resection

Ibrahim Untan

Abstract

Arteriovenous malformation localised to the prostate is rare. Until recently, the gold standard for diagnosis was angiography; however, this changed with the use of computed tomography and magnetic resonance imaging, which quickly became the first-line diagnostic tool. Common complaints are haematuria and lower urinary tract symptoms, for which there are no well-defined management guidelines. We present the case of a 53-year-old male patient who was treated for clotted haematuria. While the bleeding was thought to originate from an enlarged prostate, cystoscopy displayed a non-pulsatile, exophytic, active bleeding mass on the median lobe. The mass was resected transurethraly and diagnosed as arteriovenous malformation. This case shows an aberrant presentation of a vascular malformation in the prostate. The mass seemed to be constrained to a compact area without a visible plurality of arterial feeders. Since the prostate is a rare location for arteriovenous malformation, there are no well-defined treatment options. Nevertheless, the mass appears to have been successfully extracted by transurethral resection.

Keywords: Arteriovenous malformations, Haematuria, Prostate, Transurethral resection of prostate.

DOI: 10.47391/JPMA.6455

Submission completion date: 31-03-2022

Acceptance date: 14-12-2022

Introduction

Arteriovenous malformations (AVM) are rare lesions that can be congenital or acquired and have direct communication with arterioles and venules.¹ They commonly occur in the brain, neck, spine, lungs, pelvic cavity, and intestines. A number of publications on pelvic AVMs adjacent to the prostate are available, however, isolated AVMs of the prostate have not been documented at all.² Hereby, we report a case of AVM that was localised

.....
Department of Urology, Ahi Evran University, Training and Research Hospital, Kırşehir, Türkiye.

Correspondence: Ibrahim Untan. Email: ibrahimuntan@erciyes.edu.tr

ORCID ID. 0000-0002-6958-3625

to the prostatic median lobe, which mimicked bleeding due to a bladder tumour or enlarged prostate, and was symptomized with clotted gross haematuria.

Case Report

A 53-year-old man presented at the Department of Urology, Ahi Evran University, Training and Research Hospital, Kırşehir, Türkiye, in August 2020, with clotted gross haematuria for three days and increased lower urinary tract symptoms (LUTS) for six months. The patient reported having episodes of painless gross haematuria for four years regularly, without LUTS and clotting. He had no medical history of trauma, surgery, or prescribed medications. He responded well to single daily dose of 0.4 mg Tamsulosin Hydrochloride, which was prescribed in the subsequent bleeding episode. His only chronic ailment, hypertension, was brought under control with a single daily dose of 16 mg Candesartan Cilexetil. Digital-rectal findings were haemorrhoids grade III, with a soft consistency and no nodules. The laboratory urinalysis showed a multitude of erythrocytes per high-power field. Prothrombin time, partial thromboplastin time, and complete blood count were within normal limits. The prostate size measured by suprapubic ultrasonography was 79 ml. The patient's prostate-specific antigen level was 1.5 ng/ml, which is consistent with his age. Computed tomography (CT) of the pelvic area indicated an enlarged prostate. No gross vascular pathology was detected. A cystoscopy under spinal anaesthesia revealed a non-pulsatile, exophytic, active bleeding mass on the prostatic median lobe. The mass, approximately 1 x 1 cm in size, had a rough and wavy surface. The meandering mass could not be distinguished from a stemless bladder tumour (Fig. 1). The prostatic passage was narrow and the rest of the bladder was ordinary other than moderate trabeculation. To rule out malignancy and stop the bleeding, a transurethral resection (TUR) biopsy of the haemorrhagic area was performed without complication. The passage-widening intervention was postponed until there was a clean pathology result. Haematuria dramatically ceased, and the patient was discharged after the Foley catheter was removed.

At the end of 10 days, using Tamsulosin Hydrochloride 0.4 mg once daily, no complaints occurred. Histological

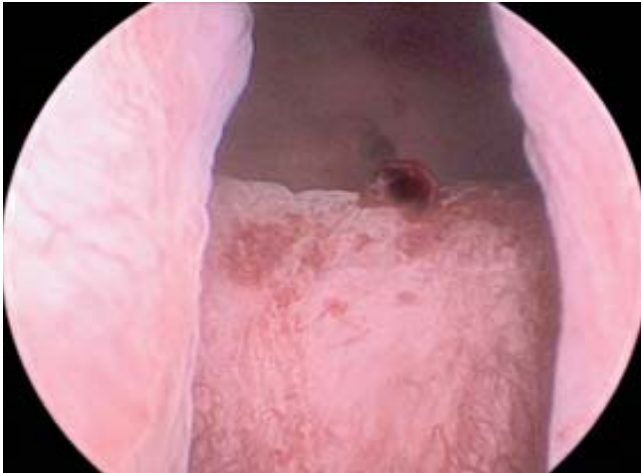


Figure-1: The cystoscopic view of the dark and raised arteriovenous malformation with active bleeding in its base surrounded by haemorrhagic mucosal area.

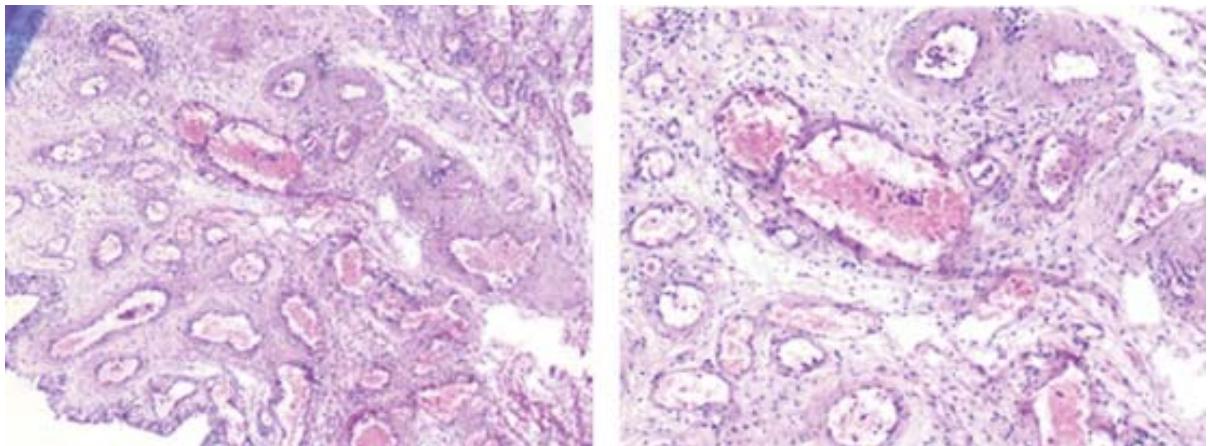


Figure-2(a-b) : Proliferation of arteries, veins, and capillary structures in the oedematous, fibrotic stroma under the prostatic urethral epithelium in two different sections (H&E, x100).

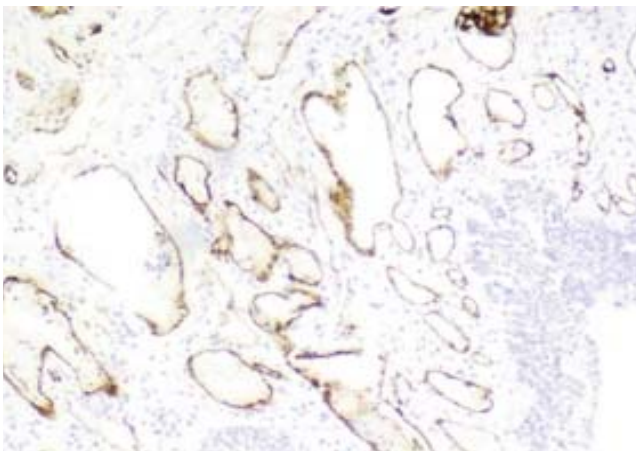


Figure-3: Vascular structures are positively stained with CD34 (x100).

sections of the specimen revealed numerous vascular structures of various sizes and thicknesses, consisting of arteries, ecstatic veins, and capillaries in a fibromuscular stroma surrounded by urothelial epithelium (Fig. 2). Endothelial cells were positively stained with CD31 and CD34 (Fig. 3). Following this, TUR of the prostate was planned and performed successfully. The prostate tissue was resected to remove the remaining AVM areas and widen the passage. The patient has not needed alpha-blockers since then and is free of haematuria. In the histopathological examination of the TUR material examined the second time, the area with an organised vascular proliferation was not observed, but fibromuscular hyperplasia was quite prominent.

Discussion

AVMs, which are snarled tangles of arteries, veins, and

small vessels connected to each other, are defects in the vascular system. They interfere with blood circulation in an organ. Though the cause is unknown, AVMs probably develop during the late somite stage in the fourth to eighth week of embryonic life. Early in the third week of embryonic life, angioblasts commence differentiating from the mesoderm, forming syncytial islands. These small clumps of cells develop tiny sprouts that interconnect the cell groups, forming a syncytial plexus that later differentiates into the primordial vascular plexus; this contains afferent, efferent, and capillary portions. AVMs can be congenital or acquired and can exist anywhere, but they are more common in the central nervous system. An AVM of the prostate, with variable symptoms and signs depending on localisation, is extremely rare.³ AVMs occur in females more often than in males.⁴ The index case was a 53-year-old middle-aged man with AVM on his prostate. His presentation showed

increased severity of LUTS and clotted gross haematuria. Although angiogram is the gold standard diagnostic tool, magnetic resonance imaging and CT are helpful in establishing the diagnosis. Haemangioma generally reveals homogeneous vascular collections, such as capillaries or veins. However, in this specimen, there were mixed vascular collections, such as capillaries, arteries, and veins. No evidence of any malignancy was observed in the specimen. It was hypothesised that the vessels under the prostatic urethral epithelium may have undergone abnormal vascular proliferation to compensate for the disturbance in blood circulation, due to fibromuscular hyperplasia. The optimal treatment has not been decided, but cauterisation of the nutrient vessels or complete ligation and excision of the entire mass are crucial for efficacious surgical treatment.⁵

Percutaneous embolization has been advocated as a first-line treatment by some and as a treatment of choice for inoperable lesions by others.⁶ Symptomatic or rapidly enlarging lesions should be treated with preoperative arterial embolization, while surgical excision should be attempted only if the AVM is confined and does not involve the neighbouring organs.⁷ To ensure symptomatic relief from diffuse, large lesions that comprise the bladder, repeated arterial embolization sessions may be needed.⁸

Conclusion

Although TUR in patients with AVM may haul massive bleeding risk, this approach can avail for compact lesions of the prostate. This particular case represents an unfamiliar localisation of an AVM in the prostate.

Although there is no defined treatment for such rare conditions, this peculiar case appears to have been treated successfully by TUR. Yet, it must be kept in mind that in rare cases this may also cause haematuria.

Patient's consent: Written informed consent for publication was given by the patient.

Disclaimer: None.

Conflict of Interest: None.

Source of Funding: None.

References

1. Kulungowski AM, Schook CC, Alomari AI, Vogel AM, Mulliken JB, Fishman SJ. Vascular anomalies of the male genitalia. *J Pediatr Surg* 2011; 46: 1214-21.
2. Wan Z, Yang BC, Cao HM, Wei JH, Guo Y, Deng CH. Haemangioma of the prostate with retrograde ejaculation—a case report. *Int J Surg Case Rep* 2022; 94: 107102.
3. Serizawa RR, Norgaard N, Horn T, Vibits H. Haemangioma of the prostate—an unusual cause of lower urinary tract symptoms: case report. *BMC Urol* 2011; 11: 4.
4. Bendel EC. Incidental Pelvic Arteriovenous Malformation. *Mayo Clin Proc* 2019; 94: 2587-8.
5. Park JM, Park YK, Chang SG. Arteriovenous malformation of the urinary bladder: Treated by transurethral resection. *Int J Urol* 2005; 12: 409-11.
6. Koganemaru M, Abe T, Iwamoto R, Suenaga M, Matsuoka K, Hayabuchi N. Pelvic arteriovenous malformation treated by superselective transcatheter venous and arterial embolization. *Jpn J Radiol* 2012; 30: 526-9.
7. Choi SY, Do YS, Lee DY, Lee KH, Won JY. Treatment of a pelvic arteriovenous malformation by stent graft placement combined with sclerotherapy. *J Vasc Surg* 2010; 51: 1006-9.
8. Ashley RA, Patterson DE, Bower TC, Stanson AW. Large congenital pelvic arteriovenous malformation and management options. *Urology* 2006; 68: 203. e11-3.