

## Surgical fixation of metastatic spine fractures: 6-months experience at a cancer hospital from a developing country — an audit

Ayesha Arshad, Irfan Yousaf

### Abstract

**Objective:** To audit the outcomes in cases of surgical fixation for metastatic spine fractures at a single centre.

**Method:** The retrospective audit was conducted at the Surgical Oncology Department of the Shaukat Khanum Memorial Cancer Hospital, Lahore, Pakistan, and comprised data of all patients who underwent surgery for metastatic spine fractures from December 1, 2019, to May 31, 2020. The patients were followed up for three months after the surgery. Pre-surgery American Spinal Injury Association Impairment Scale grades were compared with post-operative grades for all the patients. Data was analysed using SPSS 20.

**Results:** Of the 16 patients, 12(75%) were females and 4(25%) were males, with an overall mean age of  $44.0 \pm 11.9$  years (range: 24–64 years). The only co-morbid was hypertension, which was present in 6(37.5%) patients. The most common primary site was breast 10(62.5%), and 12(75%) patients presented more than 12 months after the initial diagnosis. Lumbar spine was involved in 10(62.5%) cases. Pre-operative American Spinal Injury Association Impairment Scale grade was E in 8(50%) patients. Post-operatively, 14(87.5%) patients had the E grade. There was complication in 1(6.25%) case that had a post-operative wound infection.

**Conclusion:** Surgery for spinal metastases was found to be a safe and viable option for patients with metastatic spine fractures in resource-limited countries like Pakistan.

**Keywords:** Metastasis, Spine, Fractures, Surgical fixation. (JPMA 72: 296; 2022)

**DOI:** <https://doi.org/10.47391/JPMA.3459>

### Introduction

Modern-day advancement in the field of oncology has enabled prolonged survival of cancer patients. This has led to increased reporting of many metastatic complications as well, including metastatic spine fractures.<sup>1,2</sup> Hence, there is a need for development of newer techniques and treatment modalities for such patients who were previously considered non-salvageable. Surgical fixation for metastatic spine fractures is a relatively newer procedure in spine surgery and has gained immense popularity in the last two decades.<sup>3,4</sup> It enables these patients to live their days with dignity<sup>5</sup> by preventing neurological deterioration and preserving spinal stability and function. It is part and parcel of the standard of care for cancer patients all over the world and is considered to be a highly efficient and resource-effective means of treatment.<sup>5,6</sup> New techniques are coming up daily for the treatment of spine metastasis and are continuously being scrutinised and evaluated to ensure better patient-care.<sup>7-10</sup> Unfortunately, this field is less developed in Pakistan because of resource restraints and slowly-developing oncological services. Spine oncology services were started at the Shaukat Khanum Memorial Cancer Hospital (SKMCH) around the end of 2019. The

.....  
Shaukat Khanum Memorial Cancer Hospital and Research Center, Lahore, Pakistan.

**Correspondence:** Ayesha Arshad. Email: [ayeesa@hotmail.com](mailto:ayeesa@hotmail.com)

current study was planned to audit the initial results of the facility in terms of outcomes related to patients having undergone surgical fixation for metastatic spine fractures.

### Materials and Methods

The retrospective audit was conducted at the Surgical Oncology Department of the SKMCH, Lahore, Pakistan, and comprised data of all patients who underwent surgery for metastatic spine fractures from December 1, 2019, to May 31, 2020. After approval from the institutional ethics review committee, data was retrieved from the hospital database using consecutive sampling technique. All patients presenting with metastatic spine fractures and undergoing surgical fixation for metastatic spine fracture were included. Data of those managed conservatively, those who refused surgery and patients unfit for surgery was excluded.

As per institutional practice, all patients presenting with symptomatic metastatic spine in the shape of localized or neurological pain with signs or symptoms of neurological compromise, either at initial presentation or on diagnosis during admission, are referred to the Surgical Oncology Department for specialist evaluation, followed by multi-disciplinary team (MDT) discussion to decide whether or not a patient would require surgery. Usually the criteria used to identify potential candidates for surgery are patients with a prognosis of >3 months, limited spine disease, and no or extremely limited visceral metastasis.

Well-controlled primary disease is desirable. Once it has been ascertained that the patient would require surgery for spinal metastasis, informed consent is taken from the patient who is then usually kept in bed till the surgery. The surgery is carried out either on the next elective list or more urgently, depending upon the presentation. After surgery, the patient is mobilised as soon as possible, and physiotherapy is immediately started to provide maximum benefit. The patient is then referred to the Oncology Department for further treatment of the disease.

For the current study, a proforma was used to collect data, and patient identity markers were anonymised to protect confidentiality. Patients' demographic characteristics, comorbidities, primary disease, treatment received for the primary disease, time-lapse between primary diagnosis and spinal metastasis, number, location and characteristics of metastasis, spinal instability neoplastic score (SINS),<sup>11,12</sup> Tokuhashi score for baseline prognosis,<sup>13,14</sup> American Spinal Injury Association (ASIA) Impairment Scale (AIS) grading,<sup>9</sup> performance status<sup>15</sup> and Visual Analogue Scale (VAS) score for pain<sup>5</sup> before and after surgery, type of surgical procedure performed, length of hospital stay and post-operative complications were noted. The data was analysed using SPSS 20.

## Results

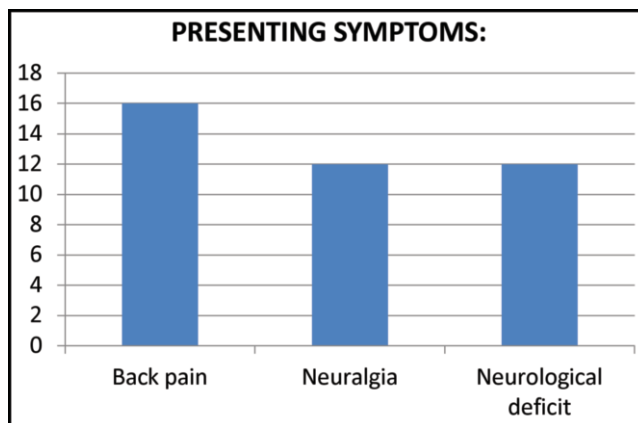
Of the 16 patients, 12(75%) were females and 4(25%) were males, with an overall mean age of 44.0±11.9 years (range: 24-64 years). The only co-morbid was hypertension, which was present in 6(37.5%) patients. As per the presenting symptoms, all patients had localised back pain, while most had neuralgia or neurological deficits (Figure-1).

The most common primary malignancy site was breast 10(62.5%). Parotid, oesophagus and chondrosarcoma were the other primary sites, each accounting for 2(12.5%) patients. Overall, 12(75%) patients presented >12 months after the primary diagnosis.

Among the patients, 10(62.5%) had surgery as well as oncological treatment for their primary malignancy prior to presenting with spinal metastasis, 4(25%) had only

**Table:** Neurological status of the patients measured using American Spinal Injury Association (ASIA) Impairment Scale (AIS).

AIS	Pre-operative	At discharge	One month after surgery	Three months after surgery
E	8	14	14	14
D	6	2	0	0
C	2	0	2	2
B	0	0	0	0
A	0	0	0	0
Total	16	16	16	16



**Figure-1:** Clinical signs and symptoms of patients at presentation.

surgery, and 2(12.5%) had had no prior treatment.

On magnetic resonance imaging (MRI), lumbar spine was found involved in 10(62.5%) cases, and thoracic spine in 6(37.5%). Also, 10(62.5%) patients had their spine involved at a single level, while 6(37.5%) had spine involvement of 2-3 levels.

Computed tomography (CT) of thorax, abdomen and pelvis showed 8(50%) patients had no metastasis elsewhere in the body. Of the remaining, 2(12.5%) patients each had metastasis at liver, lung, pancreas and mediastinum.

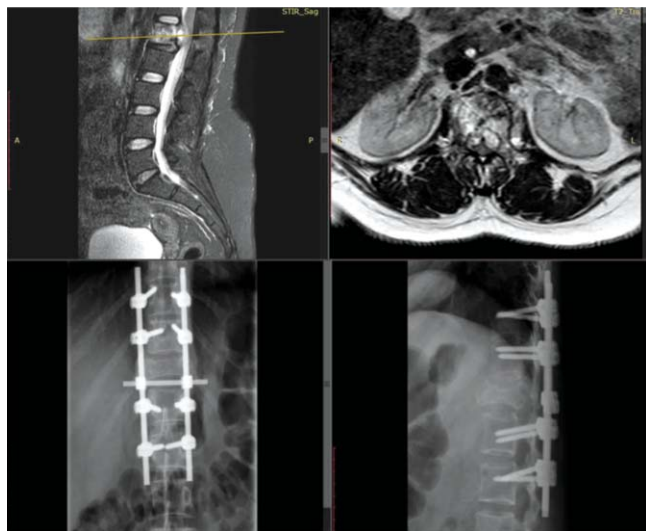
Pre-operative SINS was 7 in 1(6.25%) patient, 8 in 2(12.5%), and 10 or above in the remaining 13(81.25%).

The pre-operative performance status was 0-2 in 10(62.5%) patients and 3 in the remaining 6(37.5%). All patients had Tokuhashi score >5 (range: 7-12), meaning the expected survival was >3 months.

All the 16(100%) patients underwent posterior surgical decompression and fixation of spine. The procedure was pedicle screw fixation with screws and rods without cement augmentation. The length of fixation ranged from 5-8 levels, with 10(62.5%) patients getting spinal fixation of five levels. Mean length of hospital stay was 5.75±1.83 days (range: 4-9 days).

Pre-operative AIS grade was E in 8(50%) patients. Post-operatively, it improved and AIS grade was E in 14(87.5%) (Table). Pre-operative VAS pain scores ranged 8-10, while post-operatively, they decreased within 2 weeks of surgery to 1-5.

There was no pre-operative complication. There was 1(6.25%) case of post-operative wound infection. There was no post-operative neurological deterioration, haematoma, cerebrospinal fluid (CSF) leak, implant problems or deaths.



**Figure-2:** (A-B) Pre-operative magnetic resonance imaging (MRI) and post-operative X-rays of a middle-aged lady with metastatic breast cancer presenting with L1 metastatic lesion with epidural component causing neurological compromise and paraparesis. The patient was bed-ridden pre-operatively, and was discharged home six days after the surgery, ambulant with walker.

All patients received post-operative radiotherapy 30Gy in 10 fractions.

## Discussion

Spinal metastasis is a well-known entity since long, but till less than two decades ago, the standard treatment for the condition was steroids and radiotherapy, with surgery being attributed with less favourable results.

However, a study in 2005 changed this paradigm, and since then, it has been shifting more and more towards aggressive surgical management of spinal metastasis.<sup>2</sup>

After this landmark study, several papers were published with larger and diverse series of spine metastasis patients that validated the results and further strengthened the recommendations of surgery for spinal metastasis.<sup>11-20</sup>

If one looks closely between the old and new approaches to analyse the shift of balance in favour of surgery for spinal metastasis, one would likely ponder over the rapid advancement in the spine fixation methods over the years.<sup>1,5,7-9</sup> Metastatic spine fractures pose two kinds of problems; one is neurological compression that can be solved with decompression surgery, but the other equally important one is the stability issue, which would need proper fixation for good results.<sup>11</sup> This has been helped with new and improved methods of spinal fixation developed over time. One example of the newer techniques is minimally invasive spinal fixation to minimise the operative trauma and to achieve better results in these patients.<sup>8,9</sup> Another novel concept that has emerged is the use of separation surgery

followed by stereotactic body radiotherapy (SBRT) for spine metastasis.<sup>2,7,17</sup> All these techniques are currently under study and results are continuously being shared to analyse the efficacy and success of the different methods.<sup>7-20</sup>

When the spine oncology surgery services were started at SKMCH, there were a lot of challenges. In Pakistan, there are very few cancer hospitals, and, hence, spine oncology surgery was almost non-existent at the time. In a third world country where majority of the populace struggles to afford the basic cancer treatment, advocating metastatic spine surgery might have been difficult, but the prospect of a chance of preserving functional status is very attractive and the service was successfully established at the SKMCH (Figure 2).

Compared to contemporary international literature, the numbers in the current study are small, but the results are comparable. A 10-year study with 84 patients who underwent surgery for spinal metastases and who had a neurological deficit pre-operatively Reported post-treatment neurological improvement in 64(76.2%) patients, 19(22.6%) remained neurologically the same, and 1(1.2%) patient deteriorated neurologically.<sup>4</sup>

A series of 43 metastatic spine patients who underwent decompression and stabilisation surgery reported complications like wound infection in 9%, gluteal pressure sores in 5%, pulmonary embolism, thrombosis, dural leakage, ileus, gastritis and haemorrhagic pleural effusion in 14% patients.<sup>14</sup>

A study on 55 spinal metastasis patients undergoing spine surgery had wound infection rate of 14.5%.<sup>18</sup>

When operating for spine metastasis, one should always be striving to minimise the complications of surgery.<sup>1,3,21-23</sup> There was only one wound infection case in the current study. Unfortunately, that one patient developed progressive weakness of lower limbs later on, and became wheel-chair bound. Therefore, it of utmost importance to try to minimise the complications as that would be counter-productive to the patients, especially in a resource-limited setting.

To the best of our knowledge, this is the first case series of metastatic spine surgeries in Pakistan. Based on experience and initial results, we think spine decompression and stabilisation surgery for spinal metastasis in resource-limited countries like Pakistan is a safe and valid option and should be considered for suitable patients.

The current study has limitations as it is a single-centre, retrospective study with a small number of patients. Larger, multi-centre, prospective studies are needed to validate the results.

## Conclusion

Surgery for spinal metastases was found to be a safe and viable option for patients with metastatic spine fractures, and good results can be obtained in resource-limited countries like Pakistan.

**Disclaimer:** None.

**Conflict of Interest:** None.

**Source of Funding:** None.

## References

1. Yahanda AT, Buchowski JM, Wegner AM. Treatment, complications, and outcomes of metastatic disease of the spine: from Patchell to PROMIS. *Ann Transl Med* 2019; 7: 216.
2. Patchell RA, Tibbs PA, Regine WF, Payne R, Saris S, Kryscio RJ, et al. Direct decompressive surgical resection in the treatment of spinal cord compression caused by metastatic cancer: a randomised trial. *Lancet* 2005; 366: 643-8.
3. Bakar D, Tanenbaum JE, Phan K, Alentado VJ, Steinmetz MP, Benzel EC, et al. Decompression surgery for spinal metastases: a systematic review. *Neurosurg Focus* 2016; 41: E2.
4. Cofano F, Di Perna G, Alberti A, Baldassarre BM, Ajello M, Marengo N, et al. Neurological outcomes after surgery for spinal metastases in symptomatic patients: Does the type of decompression play a role. A comparison between different strategies in a 10-year experience. *J Bone Oncol* 2020; 26: 100340.
5. Bouthors C, Prost S, Court C, Blondel B, Charles YP, Fuentes S, et al, SOFCOT. Outcomes of surgical treatments of spinal metastases: a prospective study. *Support Care Cancer* 2020; 28: 2127-35.
6. Itshayek E, Candanedo C, Fraifeld S, Hasharoni A, Kaplan L, Schroeder JE, et al. Ambulation and survival following surgery in elderly patients with metastatic epidural spinal cord compression. *Spine J* 2018; 18: 1211-21.
7. Di Perna G, Cofano F, Mantovani C, Badellino S, Marengo N, Ajello M, et al. Separation surgery for metastatic epidural spinal cord compression. A qualitative review. *J Bone Oncol* 2020; 25: 100320.
8. Maseda M, Uei H, Nakahashi M, Sawada H, Tokuhashi Y. Neurological outcome of treatment for patients with impending paralysis due to epidural spinal cord compression by metastatic spinal tumor. *J Orthop Surg Res* 2019; 14: 291.
9. Roberts TT, Leonard GR, Cepela DJ. Classifications In Brief: American Spinal Injury Association (ASIA) Impairment Scale Clin Orthop Relat Res 2017; 47: 1499-504.
10. Conti A, Acker G, Kluge A, Loebel F, Kreimeier A, Budach V, et al. Decision Making in Patients With Metastatic Spine. The Role of Minimally Invasive Treatment Modalities. *Front Oncol* 2019; 9: 915.
11. Leone A, Cianfoni A, Zecchi V, Cortese MC, Rumi N, Colosimo C. Instability and impending instability in patients with vertebral metastatic disease. *Skeletal Radiol* 2019; 48: 195-207.
12. Fox S, Spiess M, Hnenny L, Fourney DR. Spinal Instability Neoplastic Score (SINS): Reliability Among Spine Fellows and Resident Physicians in Orthopedic Surgery and Neurosurgery. *Global Spine J* 2017; 7: 744-8.
13. Tokuhashi Y, Uei H, Oshima M, Ajiro Y. Scoring system for prediction of metastatic spine tumor prognosis. *World J Orthop* 2014; 5: 262-71.
14. Putz C, Gantz S, Bruckner T, Moradi B, Helbig L, Gerner HJ, et al. Preoperative scoring and limits of prognostication: functional outcome after surgical decompression in metastatic spinal cord compression. *Oncology* 2014; 86: 177-84.
15. Van-derZee EN, Noordhuis LM, Epker JL, Van-Leeuwen N, Wijnhoven BPL, Benoit DD, et al. Assessment of mortality and performance status in critically ill cancer patients. A retrospective cohort study. *PLoS One* 2021; 16: e0252771.
16. Zeng KL, Tseng CL, Soliman H, Weiss Y, Sahgal A, Myrehaug S. Stereotactic Body Radiotherapy (SBRT) for Oligometastatic Spine Metastases. An Overview. *Front Oncol* 2019; 9: 337.
17. Esposito M, Masi L, Zani M, Doro R, Fedele D, Garibaldi C, et al. SBRT planning for spinal metastasis: indications from a large multicentric study. *Strahlenther Onkol* 2019; 195: 226-35.
18. Majeed H, Kumar S, Bommireddy R, Klezl Z, Calthorpe D. Accuracy of prognostic scores in decision making and predicting outcomes in metastatic spine disease. *Ann R Coll Surg Engl* 2012; 94: 28-33.
19. Chang SY, Mok S, Park SC, Kim H, Chang BS. Treatment Strategy for Metastatic Spinal Tumors: A Narrative Review. *Asian Spine J* 2020; 14: 513-25.
20. Nasser R, Nakhla J, Echt M, De la Garza Ramos R, Kinon MD, Sharan A, et al. Minimally Invasive Separation Surgery with Intraoperative Stereotactic Guidance. A Feasibility Study. *World Neurosurg* 2018; 109: 68-76.
21. Li XM, Jin LB. Perioperative mortality of metastatic spinal disease with unknown primary: A case report and review of literature. *World J Clin Cases* 2021; 9: 379-88.
22. Igoumenou VG, Mavrogenis AF, Angelini A, Baracco R, Benzakour A, Benzakour T, et al. Complications of spine surgery for metastasis. *Eur J Orthop Surg Traumatol* 2020; 30: 37-56.
23. Nater A, Sahgal A, Fehlings M. Management - spinal metastases. *Handb Clin Neurol* 2018; 149: 239-55.